



DATE PRESENTING CLINICAL SIGNS

7/5/2022

Diarrhea, weight loss and muscle wasting. Deep cervical mass on L side of neck. Longstanding history of seizures. On Keppra and KBr. No seizures in several years.

PE: Quiet, pendulous abdomen with muscle wasting, BCS 3-4/9

CBC/Chem/T-4: Monocytosis, Slt decreased Plt. Normal T-4

Fecal: Hookworms, treated w/Panacur.

AUS: mild uniform splenomegaly, unremarkable GI tract.

Cervical US: ventral neck mass, 7 cm in diameter, location suspicious for thyroid adenoma or carcinoma. Potential for focal lymphadenopathy.

INTERPRETED BY

L.D. McGill, DVM,
Ph.D, DACVP

CYTOLOGY SUBMISSION

PATIENT

Neck lesion

Lilly Dubois

OBSERVATIONS

Neck lesion: Submitted are 7 videos of excellent collections of cells from the neck mass. The cellularity is demonstrating anisocytosis and anisokaryosis with bluish gray cytoplasm to minimal cytoplasm. The cytoplasmic borders are indistinct. Some of the nuclei are quite large. There are many aggregates of cells. There is some eosinophilic material.

SPECIES

Canine

INTERPRETATION OF THE FINDINGS & FURTHER RECOMMENDATIONS

Neck lesion - Thyroid carcinoma.

BREED

Austrailian Cattle Dog
Mix

COMMENTS

The cellularity is characteristic of thyroid carcinoma. The nuclei are confirming this diagnosis. The location and cellular appearance confirm the diagnosis. Excision is encouraged. A guarded prognosis is warranted.

SEX

Female Spayed

AGE

8y

WEIGHT

49 lbs

HOSPITAL NAME

Scanvet

REFERRING VET

Dr. Ebersole

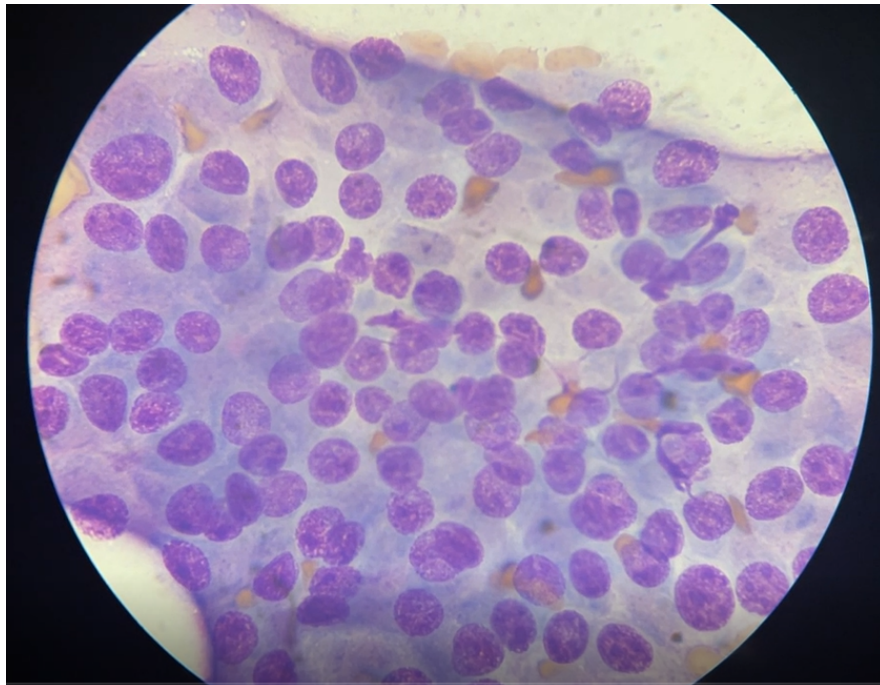


Image shows a representative group of cells collected from the neck lesion on Lilly. Note the anisokaryosis.

INVOICE NUMBER

753



DATE

7/5/2022

The information and recommendations provided are based on the images presented by the referring veterinarian. No evaluation can be communicated regarding pathology that was not visible in the image/video clips provided.

INTERPRETED BY

L.D. McGill, DVM,
Ph.D., DACVP

Thank you for this referral. If the clinical or image interpretation does not parallel your findings or if I can be of any further assistance please contact me.

PATIENT

Lilly Dubois

L.D. McGill, DVM, Ph.D., DACVP
8288 Top of the World Drive
Cottonwood Heights, UT 84121
ldmcgill.vetpath@gmail.com
cell: 801-865-1220

SPECIES

Canine

BREED

Australian Cattle Dog
Mix

SEX

Female Spayed

AGE

8y

WEIGHT

49 lbs

HOSPITAL NAME

Scanvet

REFERRING VET

Dr. Ebersole

INVOICE NUMBER

753