



**DATE PRESENTING CLINICAL SIGNS**

7/5/22

Patient presented 7/2/2022 with swelling and pain on left side of face/neck. Upon exam patient had ulceration on gingiva above 109 with open root. Submandibular lymph node enlarged. Large firm subcutaneous swelling rising from parotid area and directing ventral to wrap around neck. Sample of swelling taken via FNA.

**INTERPRETED BY**

L.D. McGill, DVM,  
Ph.D, DACVP

**CYTOLOGY SUBMISSION**

Submandibular mass

**OBSERVATIONS**

Submandibular mass: Submitted are 2 excellent videos of cells collected from the neck mass on Kira.

**PATIENT**

Kira Foley

The cellularity consists of characteristic cells. The cells are large cells with prominent cytoplasm. These cells are lipid filled cells with vacuoles. The vacuoles are irregular in size. The nuclei are eccentrically located. These are characteristic cells.

**INTERPRETATION OF THE FINDINGS & FURTHER RECOMMENDATIONS**

**SPECIES**

Canine

Submandibular mass - Lipoma

**COMMENTS**

The cellularity is a characteristic lipoma. There are no other cellular changes. No other cells are noted. There is no suggestion of malignancy. Excision is encouraged. These masses may occur in other sites independently.

**BREED**

Mix

**SEX**

Female Spayed

**AGE**

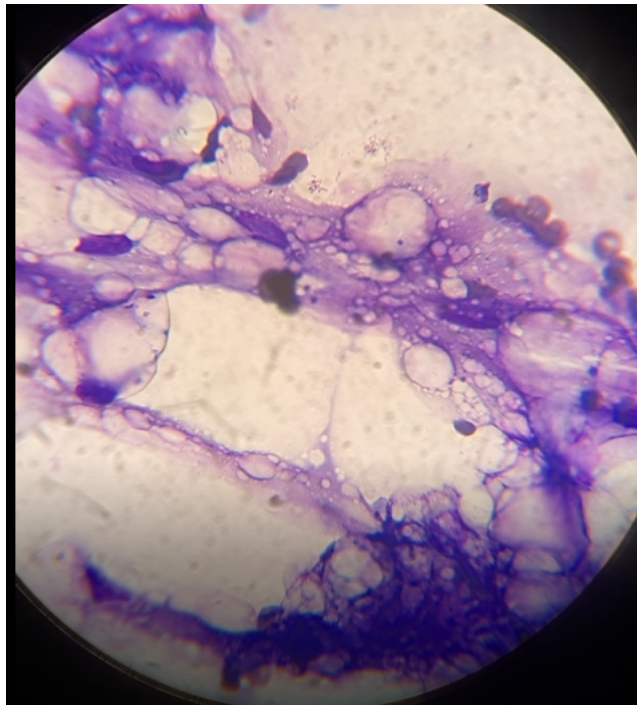
12y

**WEIGHT**

54.5#

**HOSPITAL NAME**

Rotterdam Veterinary  
Hospital



**REFERRING VET**

Dr. St Sir

Image shows irregular adipocytes collected from Kira. Note the various sized vacuoles.

**INVOICE NUMBER**

754



**DATE** 7/5/22 The information and recommendations provided are based on the images presented by the referring veterinarian. No evaluation can be communicated regarding pathology that was not visible in the image/video clips provided.

**INTERPRETED BY** L.D. McGill, DVM, Ph.D., DACVP Thank you for this referral. If the clinical or image interpretation does not parallel your findings or if I can be of any further assistance please contact me.

L.D. McGill, DVM,  
Ph.D., DACVP

**L.D. McGill, DVM, Ph.D., DACVP**  
8288 Top of the World Drive  
Cottonwood Heights, UT 84121  
ldmcgill.vetpath@gmail.com  
cell: 801-865-1220

**PATIENT**  
Kira Foley

**SPECIES**  
Canine

**BREED**  
Mix

**SEX**  
Female Spayed

**AGE**  
12y

**WEIGHT**  
54.5#

**HOSPITAL NAME**  
Rotterdam Veterinary  
Hospital

**REFERRING VET**  
Dr. St Sir

**INVOICE NUMBER**  
754