



**DATE PRESENTING CLINICAL SIGNS**

7/5/22

Chronic, intermittent UTIs, licking at the vulva and mucopurulent vulvar discharge. Exam reveals a mass-like lesion associated with region of clitoris/clitoral fossa/distal vaginal vault - nodular, thickened, firm and inflamed.  
UA - occasional WBC's, no signs of active infection

**INTERPRETED BY**

L.D. McGill, DVM,  
Ph.D, DACVP

**CYTOLOGY SUBMISSION**

Vulva mass collection

**OBSERVATIONS**

Vulva mass collection: Submitted are 5 excellent videos of excellent collections of cells from the vulva region in Dorje. The cellularity consists of packets of cells that are aggregated and occasionally individualized. They are demonstrating minimal cellular detail with marked anisocytosis and anisokaryosis. Some of the nuclei are quite large. The cellular limits are difficult to identify.

**PATIENT**

Dorje Sramek

**INTERPRETATION OF THE FINDINGS & FURTHER RECOMMENDATIONS**

**SPECIES**

Vulva mass collection - Carcinoma suggestive of urothelial carcinoma

**Canine**

**COMMENTS**

The cellularity is definitely a carcinoma. The pleomorphism for some of the tumor cells and the cytologic pattern strongly suggest urothelial carcinoma. This is likely a growth that has descended down the urinary tract from some other location up the tract. Excision of the mass will be required to confirm the diagnosis. Evaluation for additional tumor sources in the urethral tract is encouraged. A guarded to unfavorable prognosis is warranted.

**BREED**

Irish Wolfhound

**SEX**

Female Spayed

**AGE**

12y

**WEIGHT**

57#

**HOSPITAL NAME**

Ruidoso Animal Clinic

**REFERRING VET**

Dr. Favis

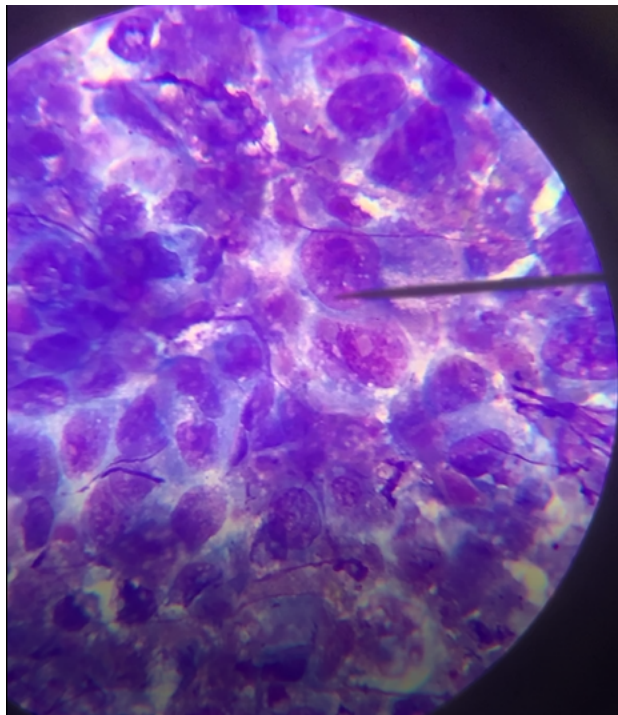


Image shows carcinoma cells with marked anisokaryosis collected from Dorje. This is a thick group of cells.

**INVOICE NUMBER**

756



**DATE**

7/5/22

The information and recommendations provided are based on the images presented by the referring veterinarian. No evaluation can be communicated regarding pathology that was not visible in the image/video clips provided.

**INTERPRETED BY**

L.D. McGill, DVM,  
Ph.D, DACVP

Thank you for this referral. If the clinical or image interpretation does not parallel your findings or if I can be of any further assistance please contact me.

**PATIENT**

Dorje Sramek

L.D. McGill, DVM, Ph.D., DACVP  
8288 Top of the World Drive  
Cottonwood Heights, UT 84121  
ldmcgill.vetpath@gmail.com  
cell: 801-865-1220

**SPECIES**

Canine

**BREED**

Irish Wolfhound

**SEX**

Female Spayed

**AGE**

12y

**WEIGHT**

57#

**HOSPITAL NAME**

Ruidoso Animal Clinic

**REFERRING VET**

Dr. Favis

**INVOICE NUMBER**

756