



DATE PRESENTING CLINICAL SIGNS

7/4/23

Dermal mast cell tumor in the inguinal area. On abdominal ultrasound - enlarged coarse spleen was found. An U/S-guided FNA was obtained.

CYTOLOGY SUBMISSION

INTERPRETED BY

Spleen

L.D. McGill, DVM,
Ph.D, DACVP

OBSERVATIONS

Spleen: Submitted are 12 excellent videos of excellent collections of cells from the spleen in Shug. The cellularity is mixed. There are large aggregates of cells that include lymphocytes and macrophages. Scattered neutrophils are associated with these aggregates. The macrophages are irregular and some contain hemosiderin. There are multiple aggregates of hemosiderin throughout this collection. Mast cells were not identified.

PATIENT

Shug Hinds

INTERPRETATION OF THE FINDINGS & FURTHER RECOMMENDATIONS

Spleen - Pyogranulomatous and lymphocytic cellular collection in the spleen with hemosiderosis.

SPECIES

Canine

COMMENTS

The cellularity in this collection does not include any mast cells. Mast cell neoplasia therefore is not part of the spleen in the collection submitted. There is a mixed cell collection with inflammation. The macrophages and hemosiderin suggest some type of hemolytic process or some type of erythrophagocytosis. No other specific malignant change or reactive process is identified. Continued monitoring of Shug is always encouraged. There could be other problems or even some type of hemolytic process.

BREED

Mixed

SEX

Female Spayed

AGE

8y

WEIGHT

43

HOSPITAL NAME

Central Veterinary
Hospital

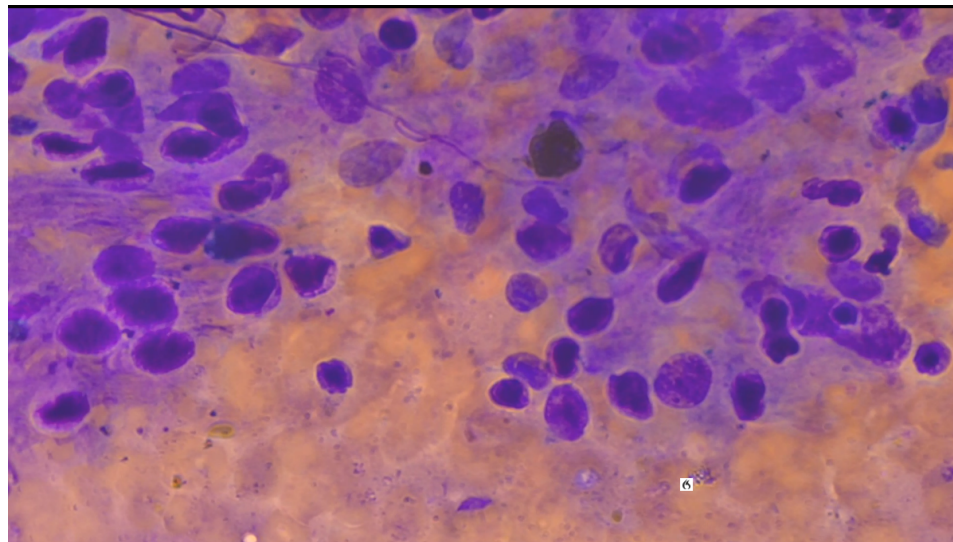


Image shows a group of cells collected from the spleen in Shug. There are lymphocytes interspersed with macrophages and a clump of hemosiderin with scattered neutrophils. Mast cells are not present.

REFERRING VET

Dr. St. Sir

The information and recommendations provided are based on the images presented by the referring veterinarian. No evaluation can be communicated regarding pathology that was not visible in the image/video clips provided.

Thank you for this referral. If the clinical or image interpretation does not parallel your findings or if I can be of any further assistance please contact me.

INVOICE NUMBER

975



DATE L.D. McGill, DVM, Ph.D., DACVP
8288 Top of the World Drive
Cottonwood Heights, UT 84121
ldmcgill.vetpath@gmail.com
cell: 801-865-1220

INTERPRETED BY

L.D. McGill, DVM,
Ph.D., DACVP

PATIENT

Shug Hinds

SPECIES

Canine

BREED

Mixed

SEX

Female Spayed

AGE

8y

WEIGHT

43

HOSPITAL NAME

Central Veterinary
Hospital

REFERRING VET

Dr. St. Sir

INVOICE NUMBER

975