



DATE PRESENTING CLINICAL SIGNS

7/30/22

Gastroenteritis, pancreatitis poss splenic mass
The spleen was enlarged and folded upon itself with scalloping contour. Mild heterogeneous parenchymal changes were noted. Palpation of the spleen is warranted to assess for any discomfort. Hypersplenism with splenic fold, possible emerging round cell neoplasia

INTERPRETED BY

L.D. McGill, DVM,
Ph.D, DACVP

CYTOLOGY SUBMISSION

Spleen

OBSERVATIONS

Spleen: Submitted are 6 excellent videos of moderate to excellent collections of cells from the spleen in Diesel. The cellularity is mixed with neutrophils, nucleated red blood cells, good aggregates of megakaryocytes, and some aggregates of lymphocytes, most of which are small mature lymphocytes. There are some aggregates of lymphocytes and macrophages in several locations in the videos. The lymphoid cells are slightly reactive but there is no suggestion of neoplasia. Scattered eosinophils are identified.

PATIENT

Diesel Bennett

SPECIES

Canine

INTERPRETATION OF THE FINDINGS & FURTHER RECOMMENDATIONS

Spleen - Mild, chronic splenitis with reactive lymphoid tissue and probable lymphohistiocytic nodules.

BREED

Great Dane

COMMENTS

The changes in these videos suggest an inflammatory process with reactive lymphoid and erythroid tissue in the spleen. There are good collections of megakaryocytes in one or two fields. The nucleated red blood cells series is represented. Some of the aggregates of cells include histiocytic cells and lymphoid cells. These aggregates do not appear to be malignant but more reactive to inflammation. With the cells present in these videos, it is my opinion that the spleen is reacting to inflammation in other locations. This could be due to pancreatitis and gastroenteritis. There is no suggestion of malignancy or primary splenic change in these videos. A guarded prognosis is warranted in Diesel since the spleen appears to be responding secondarily.

AGE

4y

WEIGHT

122

HOSPITAL NAME

Rockaway Animal
Hospital

REFERRING VET

Dr. Maniar

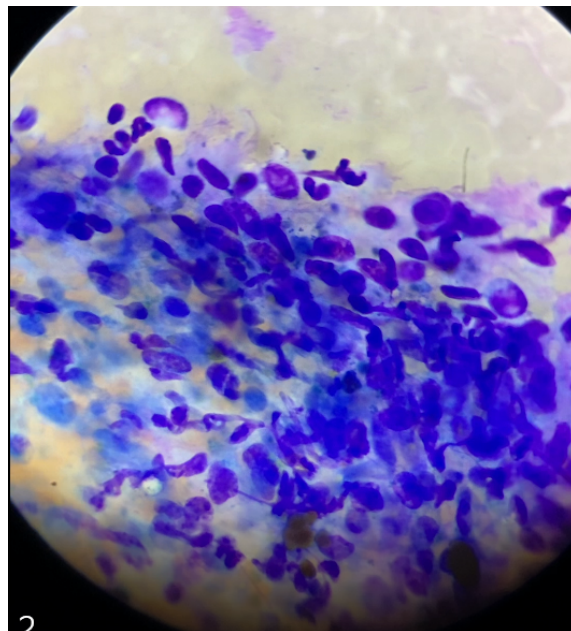


Image shows a field of cells collected from the spleen in Diesel. There is a mixture of lymphocytes and macrophages. Neutrophils are present.

INVOICE NUMBER

767



DATE

7/30/22

The information and recommendations provided are based on the images presented by the referring veterinarian. No evaluation can be communicated regarding pathology that was not visible in the image/video clips provided.

INTERPRETED BY

L.D. McGill, DVM,
Ph.D, DACVP

Thank you for this referral. If the clinical or image interpretation does not parallel your findings or if I can be of any further assistance please contact me.

PATIENT

L.D. McGill, DVM, Ph.D., DACVP
8288 Top of the World Drive
Cottonwood Heights, UT 84121
ldmcgill.vetpath@gmail.com
cell: 801-865-1220

SPECIES

Canine

BREED

Great Dane

SEX

Male Neutered

AGE

4y

WEIGHT

122

HOSPITAL NAME

Rockaway Animal
Hospital

REFERRING VET

Dr. Maniar

INVOICE NUMBER

767