



DATE PRESENTING CLINICAL SIGNS

7/30/22

Acute onset of vomiting after eating large amount of cat treats. There is a history that the cat eats less in general

INTERPRETED BY

L.D. McGill, DVM,
Ph.D, DACVP

On PE, a hard structure could be palpated in the mid abdomen. US showed it to be a highly enlarged jejunal lymph node - approximately 1.3cm wide. There was generalised lymphadenopathy in the abdomen. FNA was taken from the largest jejunal lymph node and submitted. The albumin to globulin ratio is 0.44 and the cat is positive for the FIP antibody, raising the suspicion for dry form of FIP. There was pyrexia, 39.5

CYTOLOGY SUBMISSION

Lymph node

PATIENT

Bob Cheryl

OBSERVATIONS

Lymph node: Submitted are hazy videos of some of the collections of cells that are minimal from the lymph node in Bob. The majority of the cells are lymphocytes with scattered neutrophils. The number of nucleated cells is minimal. Malignant criteria cannot be identified. Inflammation is present but minimal. There is massive ultrasound gel contamination. The videos are slightly out of focus.

SPECIES

Feline

INTERPRETATION OF THE FINDINGS & FURTHER RECOMMENDATIONS

Lymph node - Minimal cellularity with a suggestion of mild suppurative lymphadenitis and reactive lymphoid tissue.

BREED

Domestic Shorthair

COMMENTS

The cellularity in the video submitted is minimal. The majority of the cells are lymphocytes supporting reactive lymphoid tissue. There is mild inflammation with a few neutrophils. This could be secondary to FIP or could be secondary to other types of inflammatory processes. Changes of neoplasia are not suggested. This could also be a markedly reactive lymph node in the abdominal cavity of a young cat. If problems continue, exploratory and biopsy will likely be necessary since there are so few nucleated cells in this collection. Make certain to focus on the camera and not the eyepieces to get good focus on the images.

SEX

Male

AGE

3y11m

WEIGHT

3.25

HOSPITAL NAME

City Veterinary Clinic
Alain

REFERRING VET

Dr. Inam ul haq

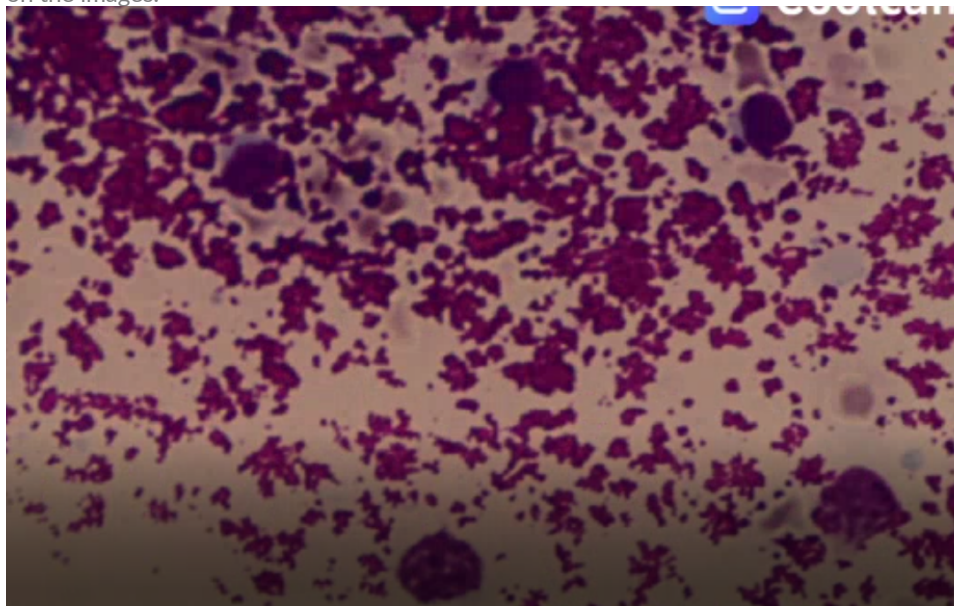


Image shows marked contamination with ultrasound gel and scattered lymphocytes collected from Bob. There are very few inflammatory cells in any field.

INVOICE NUMBER

766



DATE

7/30/22

The information and recommendations provided are based on the images presented by the referring veterinarian. No evaluation can be communicated regarding pathology that was not visible in the image/video clips provided.

INTERPRETED BY

L.D. McGill, DVM,
Ph.D, DACVP

Thank you for this referral. If the clinical or image interpretation does not parallel your findings or if I can be of any further assistance please contact me.

PATIENT

Bob Cheryl

L.D. McGill, DVM, Ph.D., DACVP
8288 Top of the World Drive
Cottonwood Heights, UT 84121
ldmcgill.vetpath@gmail.com
cell: 801-865-1220

SPECIES

Feline

BREED

Domestic Shorthair

SEX

Male

AGE

3y11m

WEIGHT

3.25

HOSPITAL NAME

City Veterinary Clinic
Alain

REFERRING VET

Dr. Inam ul haq

INVOICE NUMBER

766