



DATE PRESENTING CLINICAL SIGNS

7/27/23

Patient presented today to check a growth on the left front leg. There is a black wart like nodule present on the mid-forearm. Owner first noticed in December, but area got smaller, so owner continued to monitor area. But patient has been licking at the area and the nodule has gotten larger. (Picture of nodule also included) Nodule measures 10mm X 8mm X 10mm - 5mm deep
Fine needle aspirate was collected to rule out a Melanoma.

INTERPRETED BY

L.D. McGill, DVM,
Ph.D, DACVP

CYTOLOGY SUBMISSION

Dermal

PATIENT OBSERVATIONS

Abbey Czerniakowski

Skin mass: Submitted are 4 images and 5 excellent videos of cells collected from the skin mass on Abby. There is a paucity of nucleated cells. The majority of the cells are inflammatory cells including large numbers of neutrophils. There are scattered platelets interspersed with the surrounding red blood cells. This cellularity very likely is secondary to what may be occurring in this skin mass. There were rare round cells but so few in numbers that they could not be identified. There are scattered lymphocytes. Scattered macrophages were identified.

SPECIES

Canine

BREED

Airedale

INTERPRETATION OF THE FINDINGS & FURTHER RECOMMENDATIONS

Skin mass - Hemorrhagic aspirate with evidence of inflammation.

SEX COMMENTS

Female Spayed

The collection submitted includes hemorrhage and inflammation. The inflammation may be representative of what is occurring in circulation. There is no suggestion of malignancy or any specific proliferative process. The fact that there are few other cells besides hemorrhage and inflammation supports the possibility of some type of low-grade proliferative process such as a sebaceous gland adenoma or basal cell tumor. These structures can be more difficult to aspirate. Re-aspiration or excision of the mass with a follow-up biopsy is encouraged.

AGE

11yrs

WEIGHT

55lbs

Cytologically I am unable to identify neoplasia in the collection. The videos are excellent of the cells that were collected.

HOSPITAL NAME

Harveys Lake Veterinary
Clinic

REFERRING VET

Dr. John Bucha

INVOICE NUMBER

802



DATE

7/27/23

INTERPRETED BY

L.D. McGill, DVM,
Ph.D, DACVP

PATIENT

Abbey Czerniakowski

SPECIES

Canine

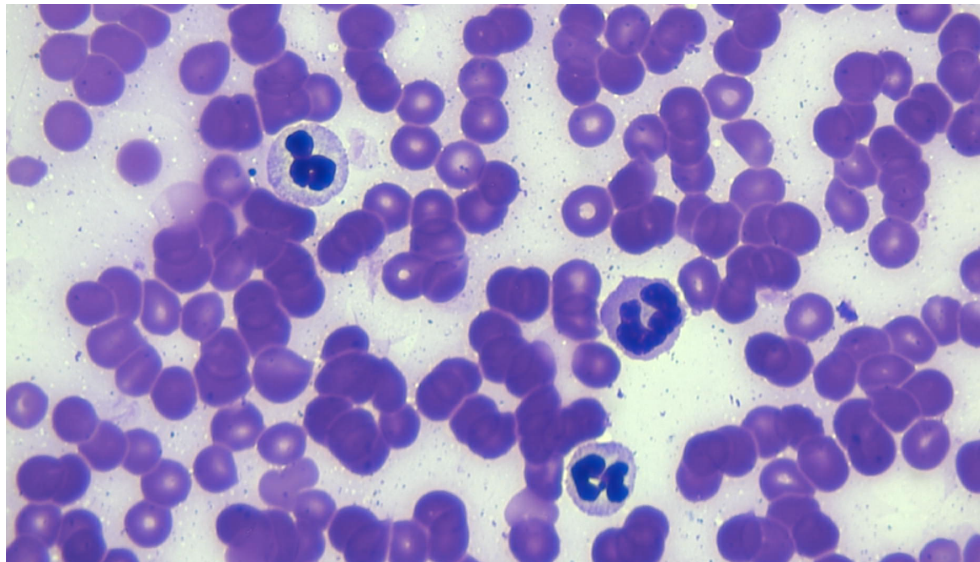


Image shows RBCs and scattered neutrophils in the collection from the skin mass on Abbey. Other nucleated cells were few.

BREED

Airedale

The information and recommendations provided are based on the images presented by the referring veterinarian. No evaluation can be communicated regarding pathology that was not visible in the image/video clips provided.

SEX

Female Spayed

Thank you for this referral. If the clinical or image interpretation does not parallel your findings or if I can be of any further assistance please contact me.

AGE

11yrs

L.D. McGill, DVM, Ph.D., DACVP
8288 Top of the World Drive
Cottonwood Heights, UT 84121
ldmcgill.vetpath@gmail.com
cell: 801-865-1220

WEIGHT

55lbs

HOSPITAL NAME

Harveys Lake Veterinary
Clinic

REFERRING VET

Dr. John Bucha

INVOICE NUMBER

802