



**DATE PRESENTING CLINICAL SIGNS**

7/25/22

weight loss, diarrhea. Heterogenous nodular splenic changes with splenic fold. R/O splenic hyperplasia vs round cell vs other. FNA of spleen performed

**INTERPRETED BY CYTOLOGY SUBMISSION**

L.D. McGill, DVM,  
Ph.D, DACVP

FNA of spleen performed

**PATIENT**

Stucka Lund-Pearson

**OBSERVATIONS**

Spleen: Submitted are 6 excellent videos of minimal collections of cells from the spleen in Stucka. The cellularity is mixed with a massive background of red blood cells. There are neutrophils, lymphocytes and nucleated RBCs. There are aggregates of macrophages with spindloid cells in some of the packets. Aggregates of hemosiderin are identified. There are some fields that include more neutrophils than other cells. There are no changes that would suggest neoplasia.

**SPECIES**

Canine

**INTERPRETATION OF THE FINDINGS & FURTHER RECOMMENDATIONS**

Spleen - Chronic suppurative splenitis with suggestions of fibrohistiocytic nodules.

**BREED**

German Shepherd

**COMMENTS**

The cellularity does not support neoplasia in this collection, but it does suggest the possibility of chronic inflammation in the spleen or draining to the spleen. This inflammation could be from other locations in the abdominal cavity. Continued evaluation of other organs including the potential of chronic pancreatitis or enteritis is encouraged. There are changes in the spleen that suggest the possibility of intravascular hemolysis with prominent hemosiderosis. The specific cause is not identified.

**SEX**

FS

**AGE**

12yr

**WEIGHT**

44.5#

**HOSPITAL NAME**

Rockaway Animal  
Hospital

**REFERRING VET**

Dr. Maniar

**INVOICE NUMBER**

40569



**DATE**

7/25/22

**INTERPRETED BY**

L.D. McGill, DVM,  
Ph.D, DACVP

**PATIENT**

Stucka Lund-Pearson

**SPECIES**

Canine

**BREED**

German Shepherd

**SEX**

FS

**AGE**

12yr

**WEIGHT**

44.5#

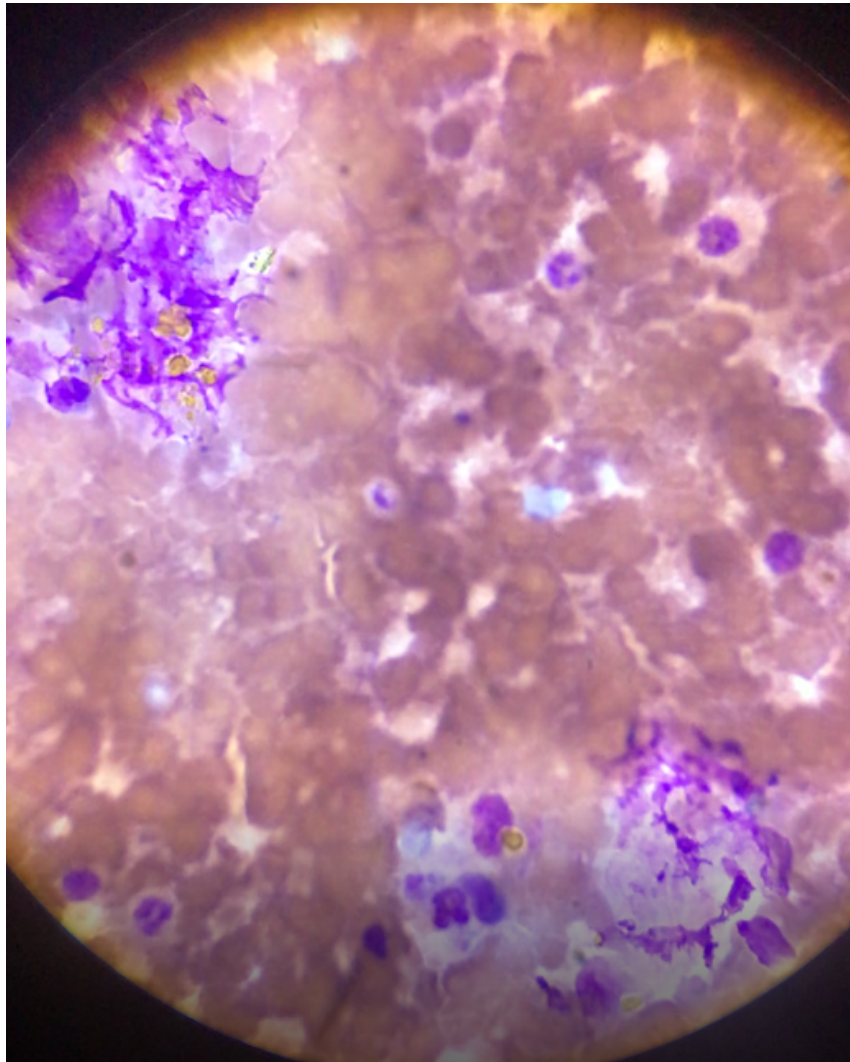


Image shows a representative field of the cells collected from the spleen in Stucka. There are hemosiderin granules with neutrophils and lymphocytes. There is a suggestion of a fibrohistiocytic nodule in the upper left.

**HOSPITAL NAME**

Rockaway Animal  
Hospital

The information and recommendations provided are based on the images presented by the referring veterinarian. No evaluation can be communicated regarding pathology that was not visible in the image/video clips provided.

Thank you for this referral. If the clinical or image interpretation does not parallel your findings or if I can be of any further assistance, please contact me.

**REFERRING VET**

Dr. Maniar

L.D. McGill, DVM, Ph.D., DACVP  
8288 Top of the World Drive  
Cottonwood Heights, UT 84121  
ldmcgill.vetpath@gmail.com  
cell: 801-865-1220

**INVOICE NUMBER**

40569



**DATE**

7/25/22

**INTERPRETED BY**

L.D. McGill, DVM,  
Ph.D, DACVP

**PATIENT**

Stucka Lund-Pearson

**SPECIES**

Canine

**BREED**

German Shepherd

**SEX**

FS

**AGE**

12yr

**WEIGHT**

44.5#

**HOSPITAL NAME**

Rockaway Animal  
Hospital

**REFERRING VET**

Dr. Maniar

**INVOICE NUMBER**

40569