



**DATE PRESENTING CLINICAL SIGNS**

7/20/22

Nickle sized erythematous alopecic nodule of right lateral thorax

**CYTOLOGY SUBMISSION**

Lateral thorax

**INTERPRETED BY**

L.D. McGill, DVM,  
Ph.D, DACVP

**OBSERVATIONS**

Lateral thoracic lesion: Submitted are 7 images collected from the lesion on the lateral thorax on Maddie. There is good cellularity in each image. The majority of the cells are larger polyhedral to slightly elongated cells. There are scattered lymphoid cells and possibly one mast cell. The larger cells have slightly vacuolated cytoplasm in most cases. Some of these cells have large nuclei. Single small nucleoli are observed.

**PATIENT**

Maddie Snyder

**INTERPRETATION OF THE FINDINGS & FURTHER RECOMMENDATIONS**

Lateral thoracic lesion - Consistent with granulomatous inflammatory reaction with large numbers of macrophages.

**SPECIES**

Canine

**COMMENTS**

The cellularity in this collection suggests a granulomatous inflammatory process. I wonder about the possibility of an injection site granuloma but I did not identify specific injection material. I considered the possibility of a soft tissue sarcoma but the cells do not support elongated cells to the degree that I would expect for that diagnosis. I even considered histiocytoma but the cells are not round enough for that diagnosis. I would expect a slightly more mixed inflammatory process but this could be some type of granulomatous inflammatory response with mainly macrophages. I would expect that excision will result in a favorable prognosis and it will likely not require wide margins.

**BREED**

Lab Mix

**SEX**

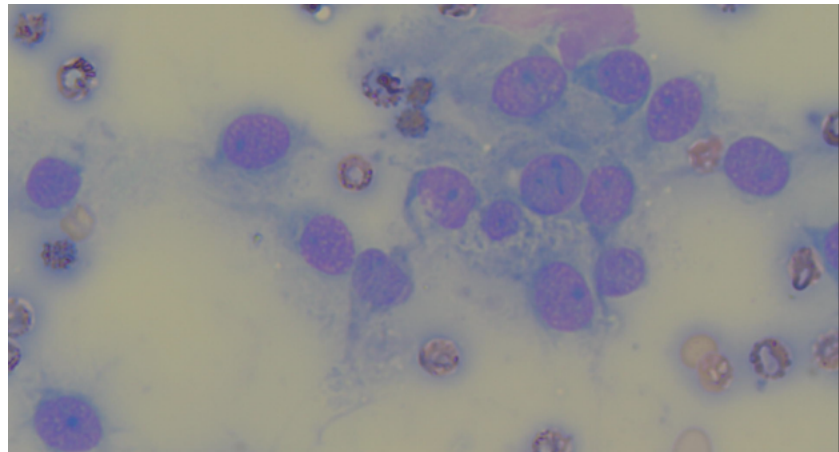
Female Spayed

**AGE**

12y

**WEIGHT**

57



**HOSPITAL NAME**

Torch Lake Veterinary  
Clinic

Image shows a group of cells collected from the lateral thoracic lesion on Maddie. Note the vacuolated cells and pleomorphic cytoplasm.

**REFERRING VET**

Dr. Waffle

The information and recommendations provided are based on the images presented by the referring veterinarian. No evaluation can be communicated regarding pathology that was not visible in the image/video clips provided.

Thank you for this referral. If the clinical or image interpretation does not parallel your findings or if I can be of any further assistance please contact me.

**INVOICE NUMBER**

761



**DATE**

7/20/22

L.D. McGill, DVM, Ph.D., DACVP  
8288 Top of the World Drive  
Cottonwood Heights, UT 84121  
ldmcgill.vetpath@gmail.com  
cell: 801-865-1220

**INTERPRETED BY**

L.D. McGill, DVM,  
Ph.D., DACVP

**PATIENT**

Maddie Snyder

**SPECIES**

Canine

**BREED**

Lab Mix

**SEX**

Female Spayed

**AGE**

12y

**WEIGHT**

57

**HOSPITAL NAME**

Torch Lake Veterinary  
Clinic

**REFERRING VET**

Dr. Waffle

**INVOICE NUMBER**

761