



**DATE PRESENTING CLINICAL SIGNS**

7/14/23

Acute respiratory distress

**INTERPRETED BY CYTOLOGY SUBMISSION**

L.D. McGill, DVM,  
Ph.D, DACVP

FNA of Lung

**PATIENT OBSERVATIONS**

Katsu Donellan

Pleural fluid: Submitted is 1 video of excellent collections of cells with excellent staining and identification of the cellularity. There are prominent neutrophils with scattered lymphoid cells and prominent reactive mesothelial cells. The mesothelial cells are reactive and demonstrate skirts around the cytoplasm which suggests pseudopodia. They are aggregated in several locations. Inflammation is the major process in this collection. There may be a few lymphocytes, but they are few in numbers and not neoplastic.

**SPECIES**

Fe

**BREED INTERPRETATION OF THE FINDINGS & FURTHER RECOMMENDATIONS**

Dlh

Pleural fluid - Chronic suppurative pleuritis with no suggestion of bacteria.

**SEX COMMENTS**

Fa

The cellularity supports an inflammatory process suggesting that inflammation is leaking from the lung or from some other process in the pleural cavity. Am unable to identify any changes that would suggest malignancy. The larger cells that you are concerned about are reactive mesothelial cells. This is occurring secondarily to the fluid buildup and inflammation. Clearing out the fluid may be beneficial in treating the condition in Katsu. A guarded prognosis is warranted since the underlying process has not been identified.

**AGE**

11

**WEIGHT**

8

**HOSPITAL NAME**

Bayshore Veterinary  
Hospital

**REFERRING VET**

Dr. Hunt

**INVOICE NUMBER**

40777



**DATE**

7/14/23

**INTERPRETED BY**

L.D. McGill, DVM,  
Ph.D, DACVP

**PATIENT**

Katsu Donellan

**SPECIES**

Fe

**BREED**

Dlh

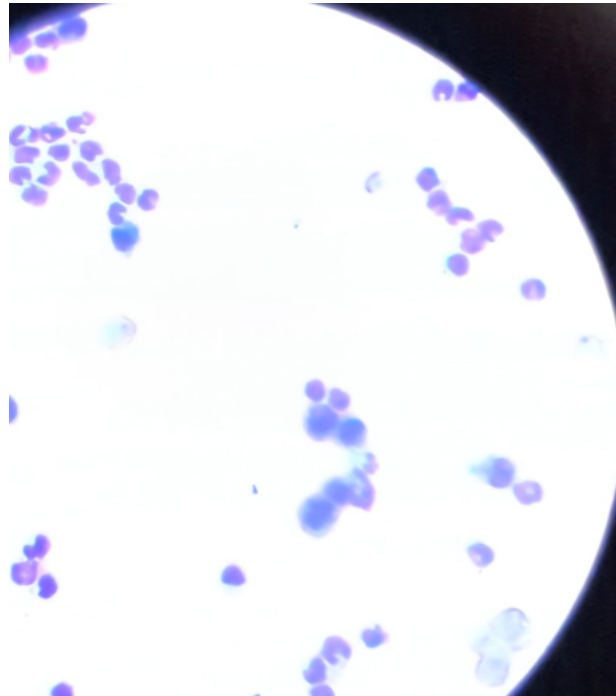


Image shows a large number of neutrophils with scattered reactive mesothelial cells. These were cells of which you were concerned collected from Katsu. There is no suggestion of malignancy.

**SEX**

Fa

The information and recommendations provided are based on the images presented by the referring veterinarian. No evaluation can be communicated regarding pathology that was not visible in the image/video clips provided.

**AGE**

11

Thank you for this referral. If the clinical or image interpretation does not parallel your findings or if I can be of any further assistance, please contact me.

**WEIGHT**

8

L.D. McGill, DVM, Ph.D., DACVP  
8288 Top of the World Drive  
Cottonwood Heights, UT 84121  
ldmcgill.vetpath@gmail.com  
cell: 801-865-1220

**HOSPITAL NAME**

Bayshore Veterinary  
Hospital

**REFERRING VET**

Dr. Hunt

**INVOICE NUMBER**

40777