



DATE **PRESENTING CLINICAL SIGNS**
7/12/22 Elevated liver enzymes, elevated Ca 2+ 13.2. episodes of seizure activity vs syncope. Ultrasound showed 3.5 cm x 6 cm cavitated left liver mass; FNA performed.

INTERPRETED BY **CYTOLOGY SUBMISSION**
Liver

L.D. McGill, DVM,
Ph.D, DACVP

OBSERVATIONS

Liver: Submitted are 6 excellent videos of moderate collections of cells from the liver in Maggie. The majority of the packets of cells are hepatocytes. There are individualized cells of this type throughout the collection. The surrounding red blood cells include a very few inflammatory cells. The hepatocytes demonstrate vacuolization and granularity. There are no characteristics of malignancy in any of the cells.

PATIENT

Maggie Friedman

INTERPRETATION OF THE FINDINGS & FURTHER RECOMMENDATIONS

Liver - Hepatocellular vacuolization and mild granularity.

SPECIES

Canine

COMMENTS

The cellularity demonstrates hepatocellular vacuolization and granularity with no evidence of malignancy or sepsis. There is mild inflammation. The changes in the liver are likely secondary to problems in other organs in the abdominal cavity in Maggie. This could be secondary to adrenal gland changes, pancreatitis or enteritis. There appear to be mild fibrosis but none of these changes are severe enough to suggest a pattern degeneration as the major process. Continued evaluation of other organs and evaluation for other diseases is encouraged.

BREED

Shih Poo

SEX

Female Spayed

AGE

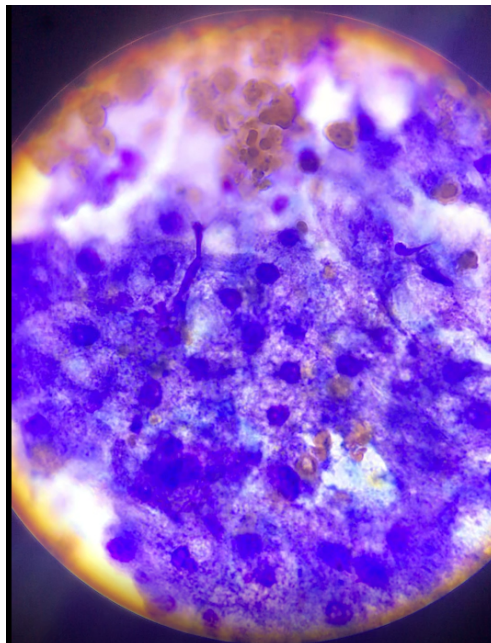
14y

WEIGHT

N/A

HOSPITAL NAME

Franklin Lakes Animal
Hospital



REFERRING VET

Dr. Hudson

Image shows hepatocellular vacuolization with mild granularity. These changes are likely secondary and suggest vacuolar hepatopathy.

INVOICE NUMBER

758



DATE 7/12/22 The information and recommendations provided are based on the images presented by the referring veterinarian. No evaluation can be communicated regarding pathology that was not visible in the image/video clips provided.

INTERPRETED BY L.D. McGill, DVM, Ph.D., DACVP Thank you for this referral. If the clinical or image interpretation does not parallel your findings or if I can be of any further assistance please contact me.

L.D. McGill, DVM,
Ph.D., DACVP

L.D. McGill, DVM, Ph.D., DACVP
8288 Top of the World Drive
Cottonwood Heights, UT 84121
ldmcgill.vetpath@gmail.com
cell: 801-865-1220

PATIENT Maggie Friedman

Maggie Friedman

SPECIES

Canine

BREED

Shih Poo

SEX

Female Spayed

AGE

14y

WEIGHT

N/A

HOSPITAL NAME

Franklin Lakes Animal
Hospital

REFERRING VET

Dr. Hudson

INVOICE NUMBER

758