



**DATE PRESENTING CLINICAL SIGNS**

6/7/22

Enlarged ln, 104 temp

**INTERPRETED BY**

**CYTOLOGY SUBMISSION**

FNA of Lymph node

L.D. McGill, DVM,  
Ph.D, DACVP

**OBSERVATIONS**

Lymph node: Submitted is an excellent video of excellent collections of cells from the lymph node in Meeka. The cellularity is almost entirely round cells of the lymphoid series. Many of these cells have nuclei that are 2 to 4 times the size of red blood cells. Many of these cells have prominent nucleoli. There are scattered structures suggesting early mitotic figures. There are scattered neutrophils and a few mature lymphocytes in the collection.

**PATIENT**

Meeka Caverly

**SPECIES**

Canine

**INTERPRETATION OF THE FINDINGS & FURTHER RECOMMENDATIONS**

Lymph node - Suggestive of early high-grade lymphoma.

**COMMENTS**

**BREED**

Shep

The collection is strongly suggestive of an early high-grade lymphoma. There is a uniformity of the cells to a more proliferative cellular process with prominent large nuclei and prominent nucleoli. There is very mild inflammation, but the inflammation appears to be secondary. If chemotherapy is contemplated, immunophenotyping of the cells in this collection may be beneficial to identify cell type. This information may contribute to the prognosis. These slides may be submitted for PARR testing or biopsy and immunohistochemistry staining can be undertaken. Re-collection for flow cytometry evaluation will be required if that testing is desired. You may wish to contact the laboratory to confirm the sample required for flow cytometry. I suspect that other slides will demonstrate the same cellularity or possibly even more aggressive lymphoid tissue. Chemotherapy may be beneficial in Meeka but a guarded to unfavorable long term prognosis is definitely warranted.

**SEX**

Fs

**AGE**

8y

**WEIGHT**

70

**HOSPITAL NAME**

Bayshore Veterinary  
Hospital

**REFERRING VET**

Dr. Hunt

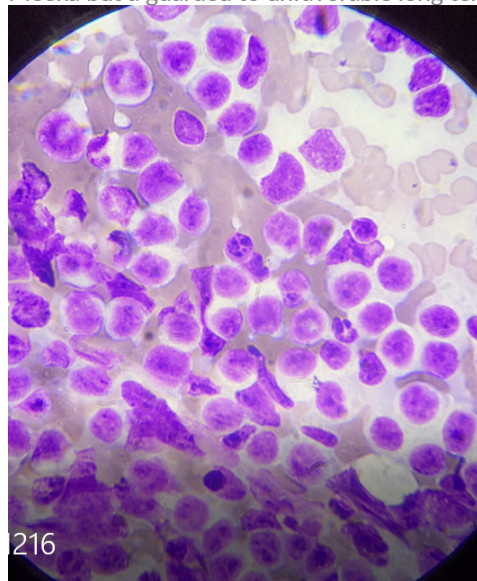


Image shows a field of large lymphoid cells with large nuclei and prominent nucleoli. There may be an early mitotic figure in the upper left area of the image.

**INVOICE NUMBER**

40538



**DATE**

6/7/22

The information and recommendations provided are based on the images presented by the referring veterinarian. No evaluation can be communicated regarding pathology that was not visible in the image/video clips provided.

**INTERPRETED BY**

L.D. McGill, DVM,  
Ph.D., DACVP

Thank you for this referral. If the clinical or image interpretation does not parallel your findings or if I can be of any further assistance, please contact me.

**PATIENT**

Meeka Caverly

**L.D. McGill, DVM, Ph.D., DACVP**  
8288 Top of the World Drive  
Cottonwood Heights, UT 84121  
ldmcgill.vetpath@gmail.com  
cell: 801-865-1220

**SPECIES**

Canine

**BREED**

Shep

**SEX**

Fs

**AGE**

8y

**WEIGHT**

70

**HOSPITAL NAME**

Bayshore Veterinary  
Hospital

**REFERRING VET**

Dr. Hunt

**INVOICE NUMBER**

40538