



DATE PRESENTING CLINICAL SIGNS

6/7/22

There is a lump in the left axilla, size like a plum movable and not ulcerated

INTERPRETED BY CYTOLOGY SUBMISSION
FNA of Left axilla - Lipoma

L.D. McGill, DVM,
Ph.D, DACVP

OBSERVATIONS

Left Axilla: Submitted is an excellent video of moderate cellular collections from the lump in the left axilla on Alfie. The cellularity is a characteristic collection of adipocytes in irregular patterns with irregular cytoplasm. There is lipid in the background which is well demonstrated in this excellent video. The nuclei are near the edge of the cells with prominent cytoplasm. Malignant characteristics are not identified.

PATIENT
Alfie

SPECIES INTERPRETATION OF THE FINDINGS & FURTHER RECOMMENDATIONS
Left axilla - Lipoma

Canine

COMMENTS

Sample This is an excellent collection of lipoma cells with lipid in the background. The video is very good. This cellularity is characteristic of a benign lipoma. Excision of these lesions is encouraged since they will continue to grow. Alfie may have these growths occur in other parts of the body and thus should be continually monitored for independent growths. Complete excision of these lesions generally results in a favorable prognosis.

BREED
Labrador

SEX
Male

AGE
9 years 4 months

WEIGHT
30

HOSPITAL NAME
City Veterinary Clinic
Alain

REFERRING VET
Dr. Inam ul haq

INVOICE NUMBER
40537

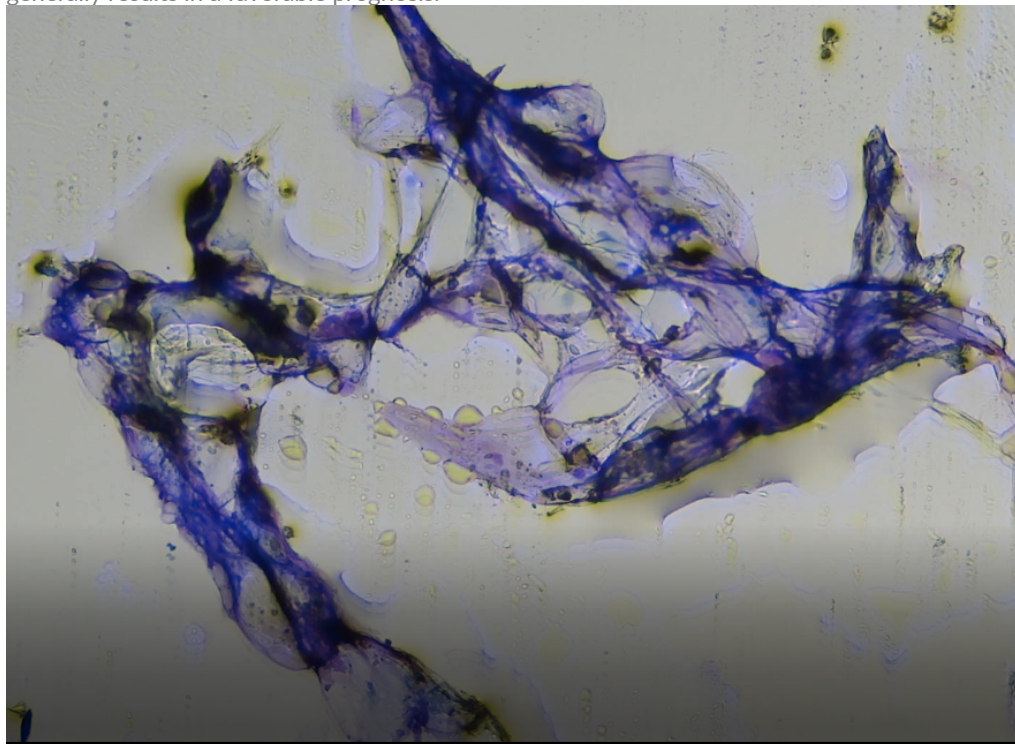


Image shows a very good collection of adipocytes from the left axilla on Alfie. There is prominent lipid as well.



DATE

6/7/22

The information and recommendations provided are based on the images presented by the referring veterinarian. No evaluation can be communicated regarding pathology that was not visible in the image/video clips provided.

INTERPRETED BY

L.D. McGill, DVM,
Ph.D., DACVP

Thank you for this referral. If the clinical or image interpretation does not parallel your findings or if I can be of any further assistance, please contact me.

PATIENT

Alfie

L.D. McGill, DVM, Ph.D., DACVP
8288 Top of the World Drive
Cottonwood Heights, UT 84121
ldmcgill.vetpath@gmail.com
cell: 801-865-1220

SPECIES

Canine

BREED

Labrador

SEX

Male

AGE

9 years 4 months

WEIGHT

30

HOSPITAL NAME

City Veterinary Clinic
Alain

REFERRING VET

Dr. Inam ul haq

INVOICE NUMBER

40537