



**DATE PRESENTING CLINICAL SIGNS**

6/6/22

Slides are from spleen- 2.4cm but slightly irregular contour seen on ultrasound.

**CYTOLOGY SUBMISSION**

FNA of Spleen

**INTERPRETED BY**

L.D. McGill, DVM,  
Ph.D, DACVP

**OBSERVATIONS**

Spleen: Submitted are 4 excellent videos of minimal to moderate collections of cells from the spleen in Buckey. The cellularity is mixed with an increased number of neutrophils in many fields. There are scattered nucleated red blood cells and scattered lymphocytes. There are some aggregates of lymphocytes interspersed with platelets. Platelets and stain debris are identified in some fields. Malignant characteristics are not identified.

**PATIENT**

Buckey Younes

**INTERPRETATION OF THE FINDINGS & FURTHER RECOMMENDATIONS**

Spleen - Mild mixed cell collection with evidence of suppurative inflammation.

**SPECIES**

Canine

**COMMENTS**

The cellularity in this collection is most suggestive of an inflammatory process within the spleen which is likely suppurative splenitis. There are no changes that would support neoplasia. There is mild inflammation and there is evidence of extramedullary hematopoiesis which is not unusual in the dog. This type of inflammation can be secondary to other problems in the abdominal cavity or as a systemic process in dogs. Continued monitoring for other sources of inflammation including pancreatitis, enteritis or other problems would be encouraged. Antibiotic therapy can be considered.

**BREED**

Stafford Terrier

**SEX**

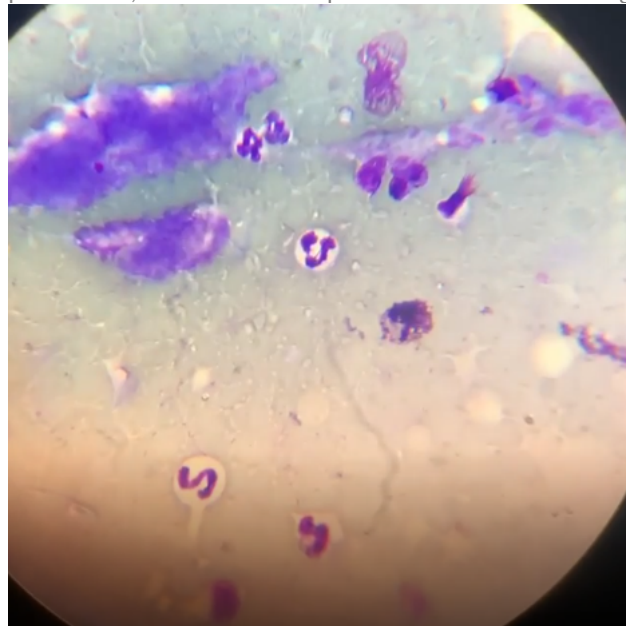
M

**AGE**

10y

**WEIGHT**

83.5



**HOSPITAL NAME**

Rotterdam Veterinary  
Hospital

Image shows scattered neutrophils and aggregates of platelets collected from the spleen in Buckey. Other fields demonstrate other cells.

**REFERRING VET**

Dr. Anna St Sir

The information and recommendations provided are based on the images presented by the referring veterinarian. No evaluation can be communicated regarding pathology that was not visible in the image/video clips provided.

**INVOICE NUMBER**

40536

Thank you for this referral. If the clinical or image interpretation does not parallel your findings or if I can be of any further assistance, please contact me.



**DATE**

6/6/22 **L.D. McGill, DVM, Ph.D., DACVP**  
8288 Top of the World Drive  
Cottonwood Heights, UT 84121  
ldmcgill.vetpath@gmail.com  
cell: 801-865-1220

**INTERPRETED BY**

L.D. McGill, DVM,  
Ph.D, DACVP

**PATIENT**

Buckey Younes

**SPECIES**

Canine

**BREED**

Stafford Terrier

**SEX**

M

**AGE**

10y

**WEIGHT**

83.5

**HOSPITAL NAME**

Rotterdam Veterinary  
Hospital

**REFERRING VET**

Dr. Anna St Sir

**INVOICE NUMBER**

40536