



DATE PRESENTING CLINICAL SIGNS

6/5/22
1.5 cm flat round hairless dermal mass recently noted.
Pt does have quite a bit of allergic skin disease but no other lesions like this one.
CBC/chems normal

INTERPRETED BY CYTOLOGY SUBMISSION

L.D. McGill, DVM,
Ph.D, DACVP

Skin

OBSERVATIONS

Skin: Submitted are 5 excellent videos of irregularly stained cells collected from the skin lesion on Hazel. There are large numbers of round cells in the collection. The majority of the round cells are small mature lymphocytes. There are reactive lymphoid cells with macrophages and neutrophils. Some of the macrophages are fairly large. Atypical cells are not prominent.

PATIENT

Hazel Bailey

INTERPRETATION OF THE FINDINGS & FURTHER RECOMMENDATIONS

Skin - Large numbers of mature lymphocytes suggesting a lymphocytic nodule or pyogranulomatous inflammation.

SPECIES

Canine

COMMENTS

There are a very few cells that could be histiocytoma cells but the majority of the cells are small lymphocytes with reactive lymphocytes present as well. I am not getting the impression that this is a lymphoma but I wonder about a cutaneous lymphoid nodule possibly as a result of a tick bite or maybe even an injection site. The other possibility is some type of foreign body penetration and there is a slight pyogranulomatous response. Excision of the lesion is not out of line but treatment with anti-inflammatories may be beneficial. If they do not decrease the size of the lesion, then there is more concern about the potential of a proliferative process. With the cells that I see, a good if completely excised prognosis is warranted.

BREED

Lab Pit x

SEX

Female Spayed

AGE

10y

WEIGHT

20kg

HOSPITAL NAME

Pacific Crest Mobile

REFERRING VET

Dr. Callihan

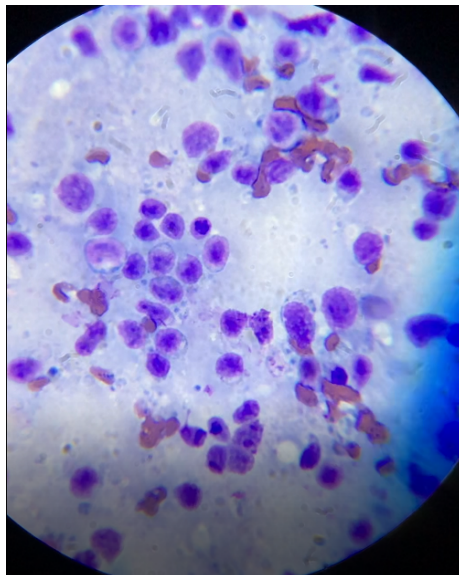


Image shows a group of cells collected from the skin lesion on Hazel. Most of the cells are small to intermediate lymphocytes and a possible macrophage or 2.

INVOICE NUMBER

741



DATE

6/5/22

The information and recommendations provided are based on the images presented by the referring veterinarian. No evaluation can be communicated regarding pathology that was not visible in the image/video clips provided.

INTERPRETED BY

L.D. McGill, DVM,
Ph.D., DACVP

Thank you for this referral. If the clinical or image interpretation does not parallel your findings or if I can be of any further assistance please contact me.

PATIENT

Hazel Bailey

L.D. McGill, DVM, Ph.D., DACVP
8288 Top of the World Drive
Cottonwood Heights, UT 84121
ldmcgill.vetpath@gmail.com
cell: 801-865-1220

SPECIES

Canine

BREED

Lab Pit x

SEX

Female Spayed

AGE

10y

WEIGHT

20kg

HOSPITAL NAME

Pacific Crest Mobile

REFERRING VET

Dr. Callihan

INVOICE NUMBER

741