



DATE PRESENTING CLINICAL SIGNS

6/5/22

The owner noticed alopecia and swelling above the upper lips. The cat delivered about 2 months ago. She is very itchy on this region and keeps on scratching there. There was folliculitis in the region of the whiskers. When I pressed one follicle, purulent discharge came out. The right upper lip was also ulcerated, looking like feline eosinophilic granuloma complex. I took an impression smear from this region and submitted for reading.

INTERPRETED BY

L.D. McGill, DVM,
Ph.D, DACVP

CYTOLOGY SUBMISSION

Skin

PATIENT

Bella Sara

OBSERVATIONS

Skin: Submitted is 1 video of several images of an impression smear of the skin from Bella. There are scattered neutrophils in each of the images and scattered keratinized cells. There is a suggestion of bacteria in one or two sites. Red blood cells are the prominent cellularity. There are no characteristics of specific other inflammation.

SPECIES

Feline

INTERPRETATION OF THE FINDINGS & FURTHER RECOMMENDATIONS

Skin - Suppurative inflammation consistent with pyoderma.

BREED

Himalyan

COMMENTS

The cellularity in this collection is minimal but includes neutrophils. This would be expected with the pus that you identified from squeezing the follicles. This suggests a bacterial infection and inflammatory process which is likely secondary. Specific etiologic agents and specific inflammatory cells to suggest an eosinophilic reaction were not identified. A deep aspiration of the region or follow-up biopsy will be required to confirm the underlying process. Impression smears on the superficial surface of skin lesions most commonly results in the type of collection you have described which is often a secondary change and not primary. If problems continue, then a deep aspiration or follow-up biopsy is encouraged. Due to the bacterial infection, antibiotic therapy may be beneficial in Bella.

SEX

Female

AGE

1y3mo

WEIGHT

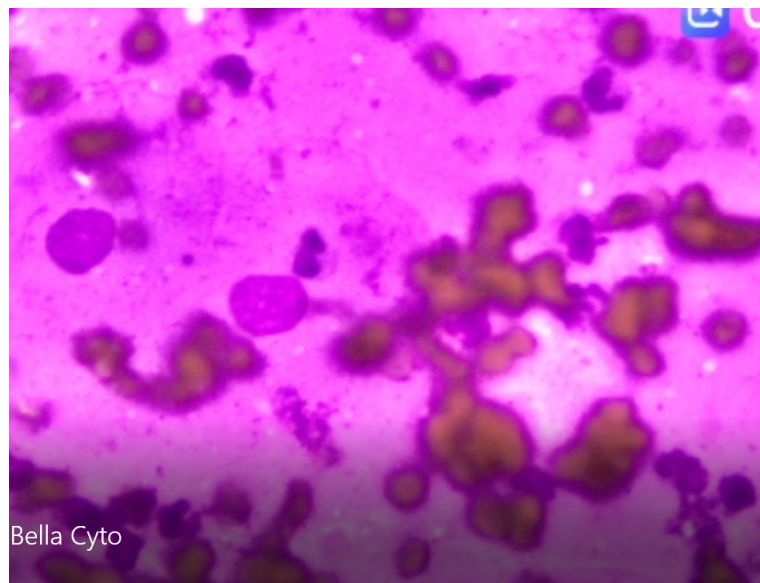
3.12kg

HOSPITAL NAME

City Veterinary Clinic
Alain

REFERRING VET

Dr. Inam ul haq



Bella Cyto

Image shows neutrophils and squamous cells collected between the interspersed RBCs from the skin impression on Bella. These cells are likely secondary and not primary.

INVOICE NUMBER

740



DATE

6/5/22

The information and recommendations provided are based on the images presented by the referring veterinarian. No evaluation can be communicated regarding pathology that was not visible in the image/video clips provided.

INTERPRETED BY

L.D. McGill, DVM,
Ph.D, DACVP

Thank you for this referral. If the clinical or image interpretation does not parallel your findings or if I can be of any further assistance please contact me.

PATIENT

Bella Sara

L.D. McGill, DVM, Ph.D., DACVP
8288 Top of the World Drive
Cottonwood Heights, UT 84121
ldmcgill.vetpath@gmail.com
cell: 801-865-1220

SPECIES

Feline

BREED

Himalyan

SEX

Female

AGE

1y3mo

WEIGHT

3.12kg

HOSPITAL NAME

City Veterinary Clinic
Alain

REFERRING VET

Dr. Inam ul haq

INVOICE NUMBER

740