



DATE PRESENTING CLINICAL SIGNS

6/30/22

Presented for acute Respiratory Distress
Labs: Normal except for Globulin of 5.4
Radiographs: Moderate Pleural Effusion

INTERPRETED BY

L.D. McGill, DVM,
Ph.D, DACVP

Unusual case. The most significant finding is moderate right atrial and mild left atrial enlargement, with biventricular dilation as well. This may reflect a primary RV cardiomyopathy in this kitten; however, ancillary pathology not visualized in this study is suspected. The finding of pleural and pericardial effusion is concerning for early decompensation and treatment is recommended as below. The left heart is mildly affected; however, this is to a lesser extent. No additional issues are identified.

CYTOLOGY SUBMISSION

PATIENT

Pleural fluid

Charlie Perry

OBSERVATIONS

Pleural fluid: Submitted are 6 excellent videos of excellent cellular collections of the fluid from the pleural cavity in Charlie. The cellularity is mixed. Neutrophils are prominent interspersed with reactive macrophages with a foamy vacuolated cytoplasm. Lymphocytes are interspersed throughout these cells. Bacteria were not identified. Some fields had large numbers of macrophages and others had few but neutrophils were prominent throughout.

SPECIES

Feline

INTERPRETATION OF THE FINDINGS & FURTHER RECOMMENDATIONS

BREED

Pleural fluid - Pyogranulomatous inflammation consistent with feline infectious peritonitis.

Maine Coon

COMMENTS

The inflammatory process is quite chronic and includes antigenic changes with lymphocytes. The sticky appearance that you noted along with these cells strongly support FIP. As you know many times the globulin levels will be higher but I have seen them be very low in cases in young cats particularly when the disease process becomes more severe. My hypothesis is that the antibodies are being used in the disease process plus the Kitty cat is not eating usually and not producing as many antibodies or as much protein as would normally occur. The lymphocytes are present but they appear to be responding to the inflammatory reaction. A PCR coronavirus antigen test may assist in confirmation. An unfavorable prognosis is warranted in my opinion.

SEX

Male

AGE

12 weeks

WEIGHT

6.7 lbs

HOSPITAL NAME

Franklin Animal Clinic

REFERRING VET

Dr. Doverspike

INVOICE NUMBER

752



DATE

6/30/22

INTERPRETED BY

L.D. McGill, DVM,
Ph.D, DACVP

PATIENT

Charlie Perry

SPECIES

Feline

BREED

Maine Coon

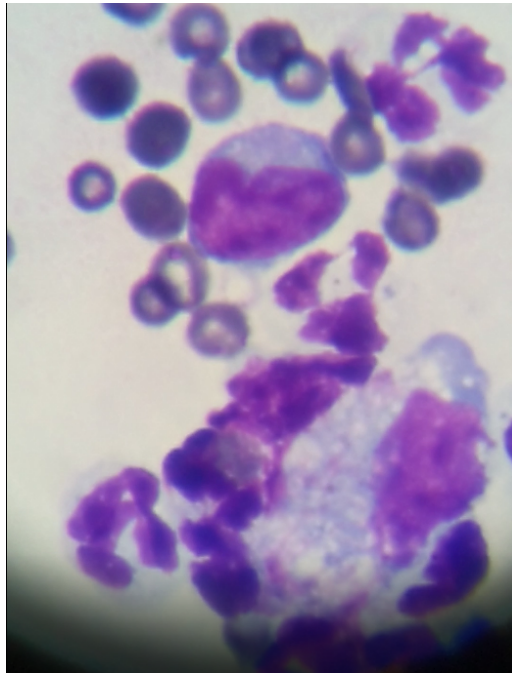


Image shows a representative collection of neutrophils and macrophages from the pleural fluid in Charlie. There is also a reactive lymphocyte.

SEX

Male

The information and recommendations provided are based on the images presented by the referring veterinarian. No evaluation can be communicated regarding pathology that was not visible in the image/video clips provided.

AGE

12 weeks

Thank you for this referral. If the clinical or image interpretation does not parallel your findings or if I can be of any further assistance please contact me.

WEIGHT

6.7 lbs

L.D. McGill, DVM, Ph.D., DACVP
8288 Top of the World Drive
Cottonwood Heights, UT 84121
ldmcgill.vetpath@gmail.com
cell: 801-865-1220

HOSPITAL NAME

Franklin Animal Clinic

REFERRING VET

Dr. Doverspike

INVOICE NUMBER

752