



DATE PRESENTING CLINICAL SIGNS

6/3/22

History of hematuria and enlarged prostate with cysts on ultrasound

INTERPRETED BY

CYTOLOGY SUBMISSION

FNA of Prostate

L.D. McGill, DVM,
Ph.D, DACVP

OBSERVATIONS

Prostate: Submitted are 4 excellent videos of moderate collections of cells from the prostate in Caesar. The cellularity is rather uniform with round euchromatic nuclei. The cytoplasm is fairly consistent, and in some cases appears to be elongated. Most of the cells are aggregated in irregular patterns. Atypia or atypical cells are not identified. There are very few inflammatory cells and the associated red blood cells.

PATIENT

Caesar Morlang

SPECIES

Canine

INTERPRETATION OF THE FINDINGS & FURTHER RECOMMENDATIONS

Prostate - Suggestive of benign prostatic epithelial hyperplasia.

COMMENTS

BREED

pitbull

I have interpreted this collection to be from the prostate, but it was not listed except for clinical history. Cytologically the cells are suggestive of benign prostatic hyperplasia. I did not identify any suggestion of neoplasia or inflammation. The concern is that Caesar is neutered, and I would expect this type of process as a result of testosterone stimulation. This causes concern as to whether there is another source for testosterone in Caesar. Evaluation for testosterone levels may be of benefit. If problems continue, then a repeat collection possibly with a traumatic catheterization of the urethra is encouraged.

SEX

Male Neutered

AGE

6y

WEIGHT

77.9

HOSPITAL NAME

Rotterdam Veterinary
Hospital

REFERRING VET

Dr. Allyson Corr

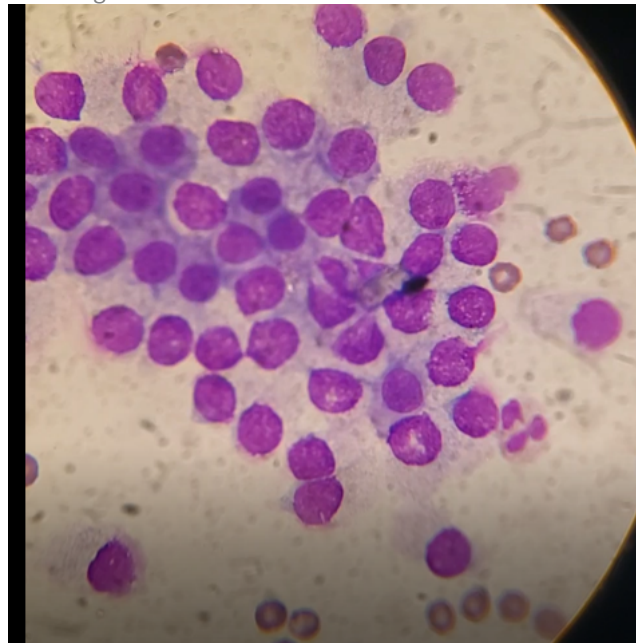


Image shows a group of cells collected from the aspirate from Caesar. The cells are rather uniform with round nuclei.

INVOICE NUMBER

40535



DATE

6/3/22

The information and recommendations provided are based on the images presented by the referring veterinarian. No evaluation can be communicated regarding pathology that was not visible in the image/video clips provided.

INTERPRETED BY

L.D. McGill, DVM,
Ph.D, DACVP

Thank you for this referral. If the clinical or image interpretation does not parallel your findings or if I can be of any further assistance, please contact me.

PATIENT

Caesar Morlang

L.D. McGill, DVM, Ph.D., DACVP
8288 Top of the World Drive
Cottonwood Heights, UT 84121
ldmcgill.vetpath@gmail.com
cell: 801-865-1220

SPECIES

Canine

BREED

pitbull

SEX

Male Neutered

AGE

6y

WEIGHT

77.9

HOSPITAL NAME

Rotterdam Veterinary
Hospital

REFERRING VET

Dr. Allyson Corr

INVOICE NUMBER

40535