



DATE PRESENTING CLINICAL SIGNS

6/28/23

Weight loss, US showed splenic microndules and scalloped contour; also swollen kidneys and chronic cholangitis liver patter. FNA of spleen performed.

INTERPRETED BY

L.D. McGill, DVM,
Ph.D, DACVP

CYTOLOGY SUBMISSION

Spleen

OBSERVATIONS

Spleen: Submitted are 4 excellent videos of very good collections of cells from the spleen in Blackjack. The cellularity is mixed. There are aggregates of neutrophils interspersed with lymphocytes, scattered macrophages, and plasma cells. There are scattered aggregates of multi nucleated cells throughout the collection. Many of these cells are binucleate. The neutrophils support an inflammatory process which is prominent in this collection. The rounded cells are large and irregular and occasionally binucleate.

PATIENT

Blackjack Kleinman

INTERPRETATION OF THE FINDINGS & FURTHER RECOMMENDATIONS

Spleen - Suggestive of round cell neoplasia which could be lymphoma or possible myeloma with chronic inflammation.

SPECIES

Feline

COMMENTS

The cellularity collected from the spleen supports a round cell neoplastic process with large irregular cells. These cells support a neoplastic round cell process but the specific cellularity is not identified in this collection. These cells could be identified by immunophenotyping the cells particularly if chemotherapy is contemplated. This may or may not be beneficial in chemotherapy. A guarded to unfavorable prognosis is warranted due to the irregular large round cells. Other tissues are likely involved and identifying this distribution could easily be beneficial in confirming the extent of the round cell neoplasia. PCR testing can be applied to the slides by some laboratories if desired to assist in confirming cell type.

BREED

DSH

SEX

Male Neutered

AGE

5y

WEIGHT

8.6#

HOSPITAL NAME

Newton Veterinary
Hospital

REFERRING VET

N/A

INVOICE NUMBER

973



DATE

6/28/23

INTERPRETED BY

L.D. McGill, DVM,
Ph.D, DACVP

PATIENT

Blackjack Kleinman

SPECIES

Feline

BREED

DSH

SEX

Male Neutered

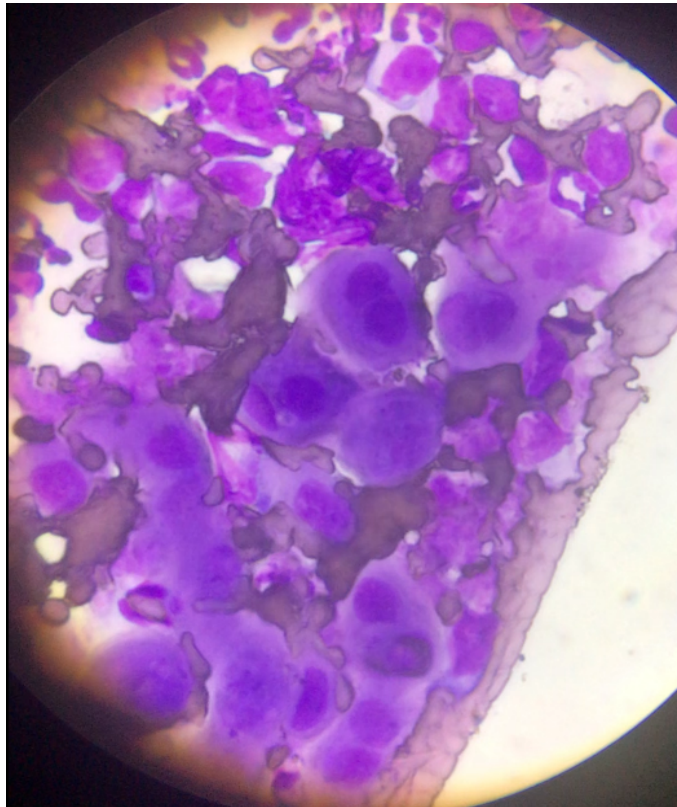


Image shows some of the large slightly irregular cells including binucleate cells and a possible mitotic figure of the cells collected from the spleen in Blackjack. There is inflammation as well as round cell neoplasia in this collection.

AGE

5y

The information and recommendations provided are based on the images presented by the referring veterinarian. No evaluation can be communicated regarding pathology that was not visible in the image/video clips provided.

WEIGHT

8.6#

Thank you for this referral. If the clinical or image interpretation does not parallel your findings or if I can be of any further assistance please contact me.

HOSPITAL NAME

Newton Veterinary
Hospital

L.D. McGill, DVM, Ph.D., DACVP
8288 Top of the World Drive
Cottonwood Heights, UT 84121
ldmcgill.vetpath@gmail.com
cell: 801-865-1220

REFERRING VET

N/A

INVOICE NUMBER

973