



**DATE PRESENTING CLINICAL SIGNS**

6/28/22

Vomiting, hematochezia. Current meds: Metro and Sucralfate. U/S Findings: Enlarged mesenteric LN  
Albumin 2.5 (2.7 L); TP 4.8 (5 L)

**INTERPRETED BY**

L.D. McGill, DVM,  
Ph.D, DACVP

**CYTOLOGY SUBMISSION**

FNA of Mesenteric lymph node

**PATIENT**

Boston Caporusso

**OBSERVATIONS**

Mesenteric lymph node: Submitted are 5 excellent videos of minimal nucleated cellularity. These were collected from the mesenteric lymph node in Boston. The cellularity is mixed and includes macrophages, small mature lymphocytes, reactive lymphocytes, neutrophils and eosinophils. There was one large aggregate of macrophages with a few spindloid cells. Malignant characteristics were not identified. There is a background of red blood cells in the collection.

**SPECIES**

Canine

**INTERPRETATION OF THE FINDINGS & FURTHER RECOMMENDATIONS**

Mesenteric lymph node - Chronic suppurative and eosinophilic inflammation suggesting pyogranulomatous lymphadenitis

**BREED**

German Shepherd

**SEX**

M-Intact

The cellularity in the few cells collected from this lymph node suggests a chronic inflammatory process. This is likely inflammation leaking from the intestine. There was no cellularity to suggest neoplasia. The inflammation appears to be stimulating eosinophils and neutrophils. This could be secondary to a heavy parasitic infestation or could be secondary to other types of intestinal inflammation. Intestinal biopsies will likely be required to identify the underlying process. The cellularity in the collection is minimal which suggests the possibility of fibrosis or other challenges in the lymph node resulting in challenges in collecting cells. Again, there is no evidence of malignancy or sepsis.

**AGE**

7yr

**WEIGHT**

85#

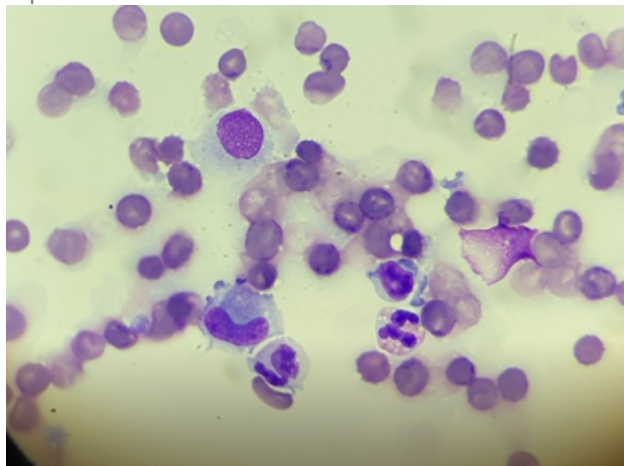


Image shows a representative group of cells collected from the mesenteric lymph node in Boston. Note the mixture including neutrophil, eosinophil and a couple of macrophages.

**HOSPITAL NAME**

Animal Mansion

**REFERRING VET**

Dr. Parker

**INVOICE NUMBER**

40557



**DATE** 6/28/22 The information and recommendations provided are based on the images presented by the referring veterinarian. No evaluation can be communicated regarding pathology that was not visible in the image/video clips provided.

**INTERPRETED BY** L.D. McGill, DVM, Ph.D., DACVP Thank you for this referral. If the clinical or image interpretation does not parallel your findings or if I can be of any further assistance, please contact me.

L.D. McGill, DVM,  
Ph.D., DACVP

**L.D. McGill, DVM, Ph.D., DACVP**  
8288 Top of the World Drive  
Cottonwood Heights, UT 84121  
ldmcgill.vetpath@gmail.com  
cell: 801-865-1220

**PATIENT**

Boston Caporusso

**SPECIES**

Canine

**BREED**

German Shepherd

**SEX**

M-Intact

**AGE**

7yr

**WEIGHT**

85#

**HOSPITAL NAME**

Animal Mansion

**REFERRING VET**

Dr. Parker

**INVOICE NUMBER**

40557