

DATE PRESENTING CLINICAL SIGNS

6/23/22

patient presented for dermal mass in groin region

INTERPRETED BY

CYTOLOGY SUBMISSION

FNA of Dermal - Suggestive of cutaneous lymphoma

L.D. McGill, DVM,
Ph.D, DACVP

OBSERVATIONS

Dermal mass: Submitted are 6 images of cells collected from the dermal mass in the groin region in the Scarlett. The cellularity in the 6 images is rather consistent with round cells. The round cells have prominent nuclei with irregular nucleoli. The cytoplasm is narrow and thin. The cytoplasm is bluish gray. There are scattered erythrocytes. The nuclei are 2 to 4 times the size of red blood cells. A mitotic figure is observed.

PATIENT

Scarlett Fries

SPECIES

INTERPRETATION OF THE FINDINGS & FURTHER RECOMMENDATIONS

Dermal mass - Suggestive of cutaneous lymphoma.

Canine

BREED

labrador

COMMENTS

The cellularity throughout these images suggests the likelihood of lymphoma. The lymphoma could be due to either B or T-cell lymphoma. There is a mitotic figure in one of the images. Evaluation of the slides by immunophenotyping may be beneficial in prognosis in the case. If chemotherapy is contemplated, then immunophenotyping of the cells to confirm the specific cell type may be beneficial for prognosis. The slides can be submitted for PCR testing or new slides that are not stained can be submitted for immunocytochemistry staining. Flow cytometry can be beneficial but will require a repeat collection of cells prior to submission to the laboratory. Contacting the laboratory to confirm how to submit flow cytometry samples is encouraged. An unfavorable prognosis is warranted but chemotherapy may be beneficial in prolonging the life in Scarlett.

AGE

9

WEIGHT

67.2

HOSPITAL NAME

Torch Lake Veterinary
Clinic

REFERRING VET

Dr. Adrienne Waffle

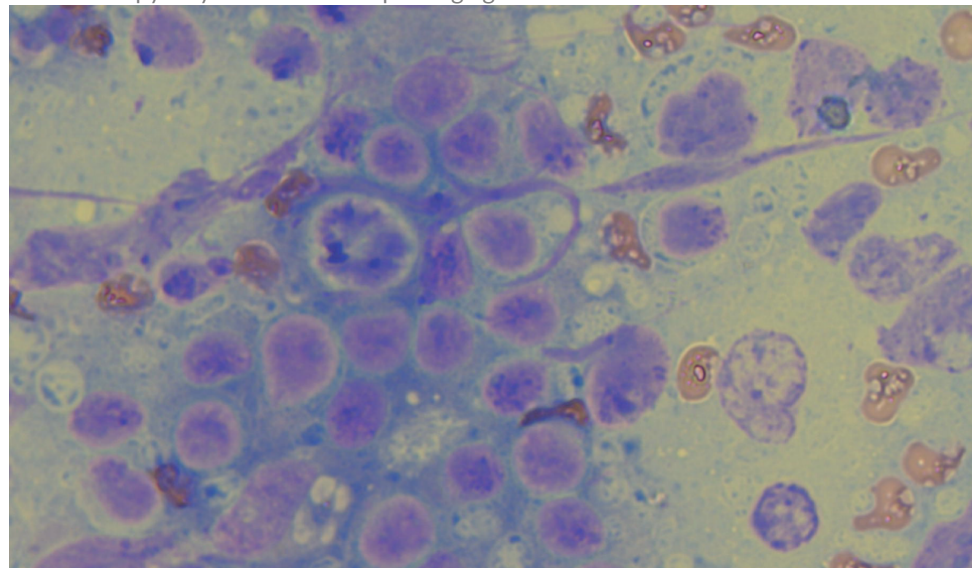
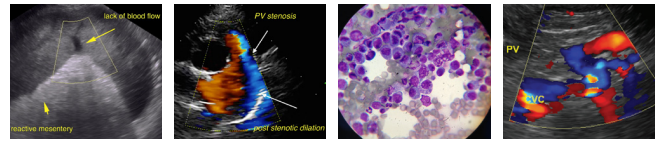


Image shows a group of large lymphocytes with a mitotic figure in the center collected from Scarlett. Biopsy will be required to confirm the diagnosis.

INVOICE NUMBER

40554



DATE 6/23/22 The information and recommendations provided are based on the images presented by the referring veterinarian. No evaluation can be communicated regarding pathology that was not visible in the image/video clips provided.

INTERPRETED BY L.D. McGill, DVM, Ph.D., DACVP Thank you for this referral. If the clinical or image interpretation does not parallel your findings or if I can be of any further assistance, please contact me.

L.D. McGill, DVM,
Ph.D., DACVP

L.D. McGill, DVM, Ph.D., DACVP
8288 Top of the World Drive
Cottonwood Heights, UT 84121
ldmcgill.vetpath@gmail.com
cell: 801-865-1220

PATIENT
Scarlett Fries

SPECIES

Canine

BREED

labrador

SEX

FS

AGE

9

WEIGHT

67.2

HOSPITAL NAME

Torch Lake Veterinary
Clinic

REFERRING VET

Dr. Adrienne Waffle

INVOICE NUMBER

40554