



**DATE PRESENTING CLINICAL SIGNS**

6/22/23

Patient presented for abdominal U/S 6/22/23. Mild liver changes noted and severely enlarged mesenteric LNs. FNA of LNs obtained for cytology.

**CYTOLOGY SUBMISSION**

**INTERPRETED BY**

Mesenteric lymph node

L.D. McGill, DVM,  
Ph.D, DACVP

**OBSERVATIONS**

Mesenteric lymph node: Submitted are 27 excellent images of cells collected from the mesenteric lymph node in Loki. The cellularity in many of the images is too dense to interpret but there are many images that are readily interpretable. Where the cells are spread out, there are large numbers of neutrophils and macrophages. The macrophages have a foamy cytoplasm. Scattered small mature lymphocytes are present. Degenerate cells and necrotic debris are present with a background of protein. Red blood cells are prominent. Malignant characteristics are not identified.

**PATIENT**

Loki Voice for the  
Voiceless

**INTERPRETATION OF THE FINDINGS & FURTHER RECOMMENDATIONS**

Mesenteric lymph node - Chronic pyogranulomatous inflammation consistent with feline infectious peritonitis.

**SPECIES**

Feline

**COMMENTS**

The cellularity in this collection supports a rather extensive chronic pyogranulomatous inflammation. There are neutrophils and there are macrophages that have a foamy to vacuolated cytoplasm. There are adequate numbers of macrophages that may be utilized to test for feline coronavirus on the slides if your laboratory will do so. There are no changes that would support neoplasia. This inflammatory process could be the result of other types of chronic inflammation but the most common in a cat is FIP. There easily could be that type of inflammatory process in the liver as well. A guarded to unfavorable prognosis is warranted. Again to confirm the diagnosis, feline coronavirus testing is encouraged.

**BREED**

DSH

**SEX**

Male Neutered

**AGE**

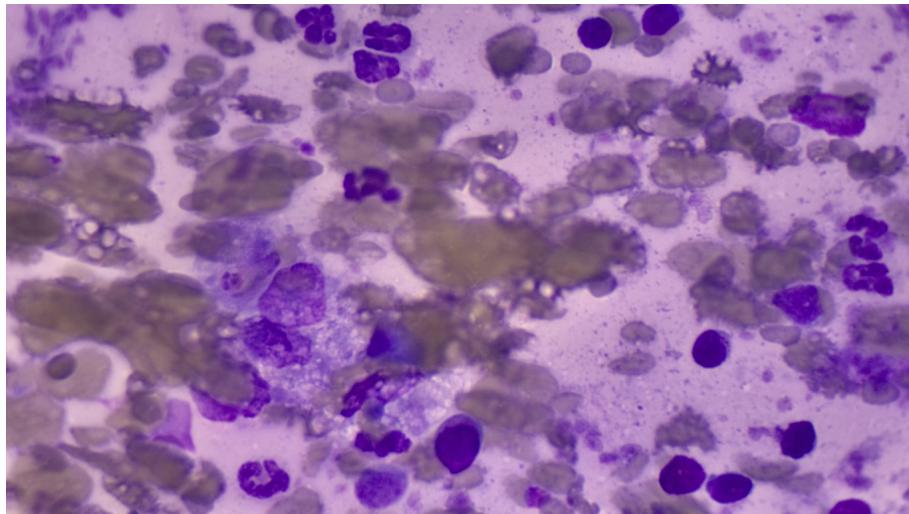
6y

**WEIGHT**

6.6 lb

**HOSPITAL NAME**

Rotterdam Veterinary  
Hospital



This image demonstrates large numbers of neutrophils with good numbers of macrophages scattered throughout. The macrophages have a foamy cytoplasm. There are small lymphocytes in the lower right corner in this collection from Loki.

**REFERRING VET**

Dr. St. Sir

The information and recommendations provided are based on the images presented by the referring veterinarian. No evaluation can be communicated regarding pathology that was not visible in the image/video clips provided.

**INVOICE NUMBER**

971



**DATE** Thank you for this referral. If the clinical or image interpretation does not parallel your findings or if I can be of any further assistance please contact me.

6/22/23

**INTERPRETED BY** **L.D. McGill, DVM, Ph.D., DACVP**  
8288 Top of the World Drive  
Cottonwood Heights, UT 84121  
ldmcgill.vetpath@gmail.com  
cell: 801-865-1220

L.D. McGill, DVM,  
Ph.D, DACVP

**PATIENT**

Loki Voice for the  
Voiceless

**SPECIES**

Feline

**BREED**

DSH

**SEX**

Male Neutered

**AGE**

6y

**WEIGHT**

6.6 lb

**HOSPITAL NAME**

Rotterdam Veterinary  
Hospital

**REFERRING VET**

Dr. St. Sir

**INVOICE NUMBER**

971