



**DATE PRESENTING CLINICAL SIGNS**

6/22/23

Firm 1 cm SQ mass R shoulder. It is mobile. O noticed yesterday. Doesn't seem to be bothering p.

**INTERPRETED BY CYTOLOGY SUBMISSION**

L.D. McGill, DVM,  
Ph.D, DACVP

FNA of Dermal

**PATIENT OBSERVATIONS**

Buddy Leach

Subcutaneous mass: Submitted are 31 images of cells collected from the right shoulder mass on Buddy. The cellularity on the images is minimal but there is a mixture of cells throughout the large numbers of images. Neutrophils and macrophages are readily identified. There are scattered spindloid cells and even a multinucleated giant cell. A few mast cells were identified. There is a background of protein and degenerate debris. Malignant characteristics are not identified.

**SPECIES**

Canine

**INTERPRETATION OF THE FINDINGS & FURTHER RECOMMENDATIONS**

**BREED**

Lab mix

Subcutaneous mass from the right shoulder - Pyogranulomatous inflammation with necrosis and secondary fibrosis.

**SEX COMMENTS**

Male Neutered

There are fewer cells than I would like to make a good diagnosis but there is a mixture of cells supporting inflammation. This appears to be consistent throughout all of the images. There is some fibrosis and there was a multinucleated giant cell. The mast cells are present but likely the result of inflammation and not neoplasia. The multinucleated giant cell and mixture of cells suggest the possibility of foreign body reaction as well. There is no suggestion of malignancy or sepsis. There is evidence of chronic inflammation and I wonder about the possibility of a localized traumatic response or even the possibility of an injection site granuloma. Treatment for inflammation or excision of the lesion is encouraged. A good prognosis is expected with this cellularity included in these

**AGE**

6y

**WEIGHT**

81

**HOSPITAL NAME**

Torch Lake Veterinary  
Clinic

**REFERRING VET**

Dr. Hannah Morton

**INVOICE NUMBER**

40764



**DATE**

6/22/23

**INTERPRETED BY**

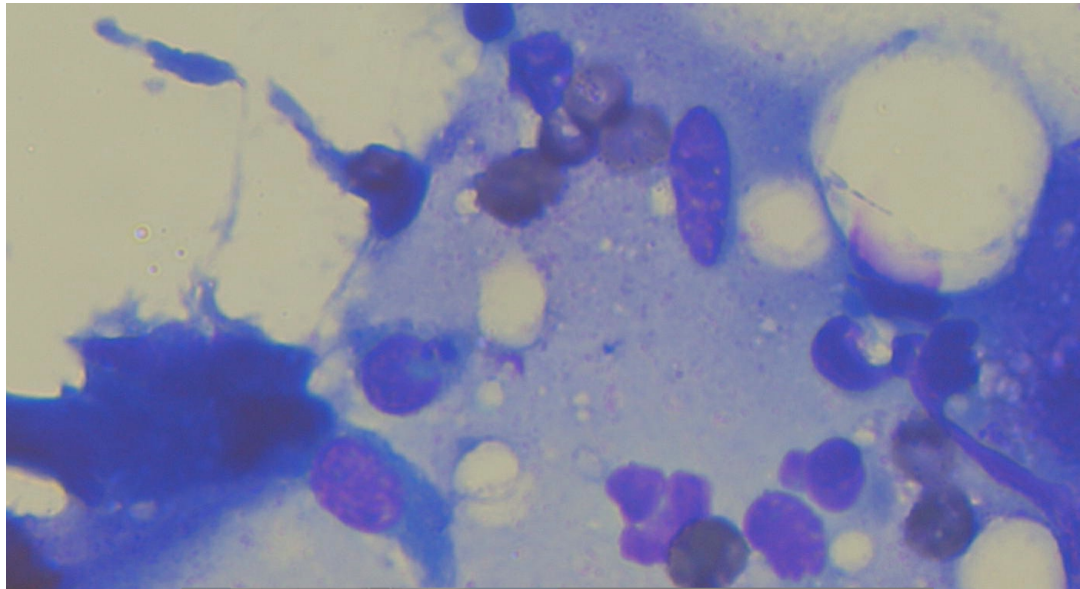
L.D. McGill, DVM,  
Ph.D, DACVP

**PATIENT**

Buddy Leach

**SPECIES**

Canine



images. Image shows representative cells including spindle cells with a protein background and lipid collected from the right shoulder on Buddy.

**BREED**

Lab mix

**SEX**

Male Neutered

**AGE**

6y

**WEIGHT**

81

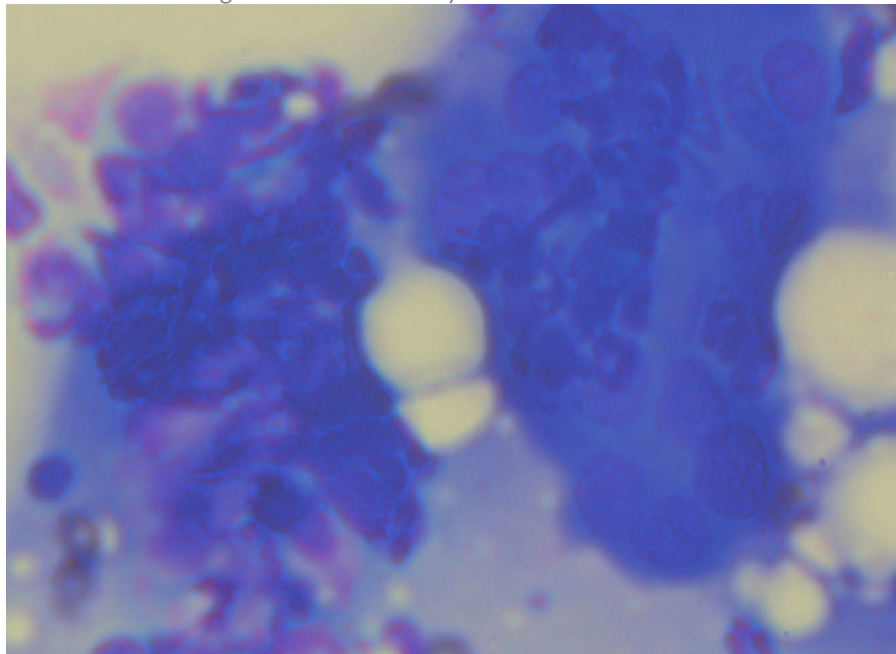


Image shows the multinucleated cell collected from the subcutaneous lesion on Buddy.

**HOSPITAL NAME**

Torch Lake Veterinary  
Clinic

**REFERRING VET**

Dr. Hannah Morton

The information and recommendations provided are based on the images presented by the referring veterinarian. No evaluation can be communicated regarding pathology that was not visible in the image/video clips provided.

**INVOICE NUMBER**

40764

Thank you for this referral. If the clinical or image interpretation does not parallel your findings or if I can be of any further assistance, please contact me.



**DATE**

6/22/23

L.D. McGill, DVM, Ph.D., DACVP  
8288 Top of the World Drive  
Cottonwood Heights, UT 84121  
ldmcgill.vetpath@gmail.com  
cell: 801-865-1220

**INTERPRETED BY**

L.D. McGill, DVM,  
Ph.D, DACVP

**PATIENT**

Buddy Leach

**SPECIES**

Canine

**BREED**

Lab mix

**SEX**

Male Neutered

**AGE**

6y

**WEIGHT**

81

**HOSPITAL NAME**

Torch Lake Veterinary  
Clinic

**REFERRING VET**

Dr. Hannah Morton

**INVOICE NUMBER**

40764