



**DATE PRESENTING CLINICAL SIGNS**

6/22/22

Patient presented 6/21/22 with large sudden ulcerated mass Left stifle. 7 x 7.5 x 4 cm2 mass dimensions. Patient has Addison's disease, hypothyroidism, and renal cysts. Labwork normal.

**INTERPRETED BY CYTOLOGY SUBMISSION**

L.D. McGill, DVM,  
Ph.D, DACVP

Dermal mass

**OBSERVATIONS**

Dermal mass: Submitted are 3 videos of moderate collections of cells from the dermal mass on Lucy. The cellularity is not particularly high. There are scattered inflammatory cells including neutrophils and lymphocytes. There are packets of cells in some locations that include slight aggregation with vacuolization of the cytoplasm. This cellularity is included only in a few fields. Degenerate debris is scattered throughout intermixed with the inflammatory cells of neutrophils and lymphocytes. There is a protein background.

**PATIENT**

Lucy Shufelt

**SPECIES INTERPRETATION OF THE FINDINGS & FURTHER RECOMMENDATIONS**

Canine

Dermal mass - Cells suggestive of a sebaceous gland adenoma with no other significant change besides inflammation.

**BREED**

Schnauzer, standard

**COMMENTS**

The cellularity in this collection is supporting the possibility of sebaceous gland adenoma with some secondary inflammation. The cellularity of proliferative elements is minimal. If problems continue, then a repeat collection or excision of the mass is suggested. The cellularity in all of the videos is benign. Excision of the mass is encouraged. If the cellularity is representative, then excision of the mass is expected to result in a favorable prognosis.

**SEX**

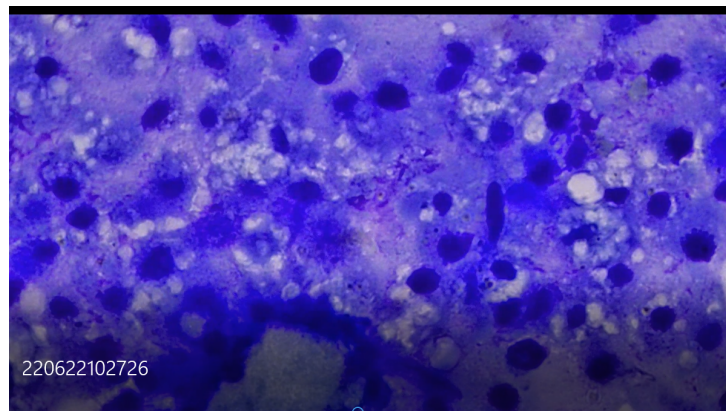
Female Spayed

**AGE**

2/15/10

**WEIGHT**

47



**HOSPITAL NAME**

Central Veterinary  
Hospital

Image shows a packet of vacuolated cells with uniform round nuclei. The vacuolization suggests sebaceous glands.

**REFERRING VET**

Dr. Hardaker

The information and recommendations provided are based on the images presented by the referring veterinarian. No evaluation can be communicated regarding pathology that was not visible in the image/video clips provided.

**INVOICE NUMBER**

750

Thank you for this referral. If the clinical or image interpretation does not parallel your findings or if I can be of any further assistance please contact me.



**DATE**

6/22/22 **L.D. McGill, DVM, Ph.D., DACVP**  
8288 Top of the World Drive  
Cottonwood Heights, UT 84121  
ldmcgill.vetpath@gmail.com  
cell: 801-865-1220

**INTERPRETED BY**

L.D. McGill, DVM,  
Ph.D, DACVP

**PATIENT**

Lucy Shufelt

**SPECIES**

Canine

**BREED**

Schnauzer, standard

**SEX**

Female Spayed

**AGE**

2/15/10

**WEIGHT**

47

**HOSPITAL NAME**

Central Veterinary  
Hospital

**REFERRING VET**

Dr. Hardaker

**INVOICE NUMBER**

750