



DATE PRESENTING CLINICAL SIGNS

6/21/22 Decreased appetite for over a week, lethargic.
BW - anemia, decreased albumin, ALT and AST. On abdominal ultrasound - large (2.5 cm) heteroechoic mass in the right pancreas, enlarged hypoechoic epigastric lymph nodes.

INTERPRETED BY

L.D. McGill, DVM,
Ph.D, DACVP

CYTOLOGY SUBMISSION

FNA of Pancreas

PATIENT

Tommy Gandy

OBSERVATIONS

Pancreas: Submitted are 8 videos of cells collected from the pancreatic region in Tommy. The cellularity consists of packets of cells that are aggregated in irregular patterns. Many of the cells have foamy granular to vacuolated cytoplasm. They appear to be piling upon each other. Nuclear characteristics are not markedly altered. The cells have bluish gray cytoplasm with the vacuolization. There are aggregates of neutrophils associated with the cells. Occasionally there are structures suggesting bacteria.

SPECIES

Feline

BREED

DSH

INTERPRETATION OF THE FINDINGS & FURTHER RECOMMENDATIONS

Pancreas - Aggregates of cells suggesting epithelial cells such as a pancreatic acinar adenoma or possible accessory liver with secondary suppurative inflammation.

SEX

Male Neutered

COMMENTS

The cellularity is demonstrating epithelial cell proliferation. These could be hepatocytes from an accessory liver nodule, or it could be the result of pancreatic acinar proliferation. Either process is benign. There are probably more characteristics to suggest pancreatic acinar tissue than hepatocellular tissue but there is some concern with both. Exploratory and excision will be required to confirm the process. There is inflammation occurring in and around the cells. This is more common with pancreatitis than with an accessory liver. Treatment for inflammation including antibiotics is encouraged. A guarded prognosis is warranted until the specific tissue type and grade of the mass can be ascertained.

WEIGHT

13

HOSPITAL NAME

Central Veterinary
Hospital

REFERRING VET

Dr. Anna St. Sir

INVOICE NUMBER

40550



DATE

6/21/22

INTERPRETED BY

L.D. McGill, DVM,
Ph.D, DACVP

PATIENT

Tommy Gandy

SPECIES

Feline

BREED

DSH

SEX

Male Neutered

AGE

11y

WEIGHT

13

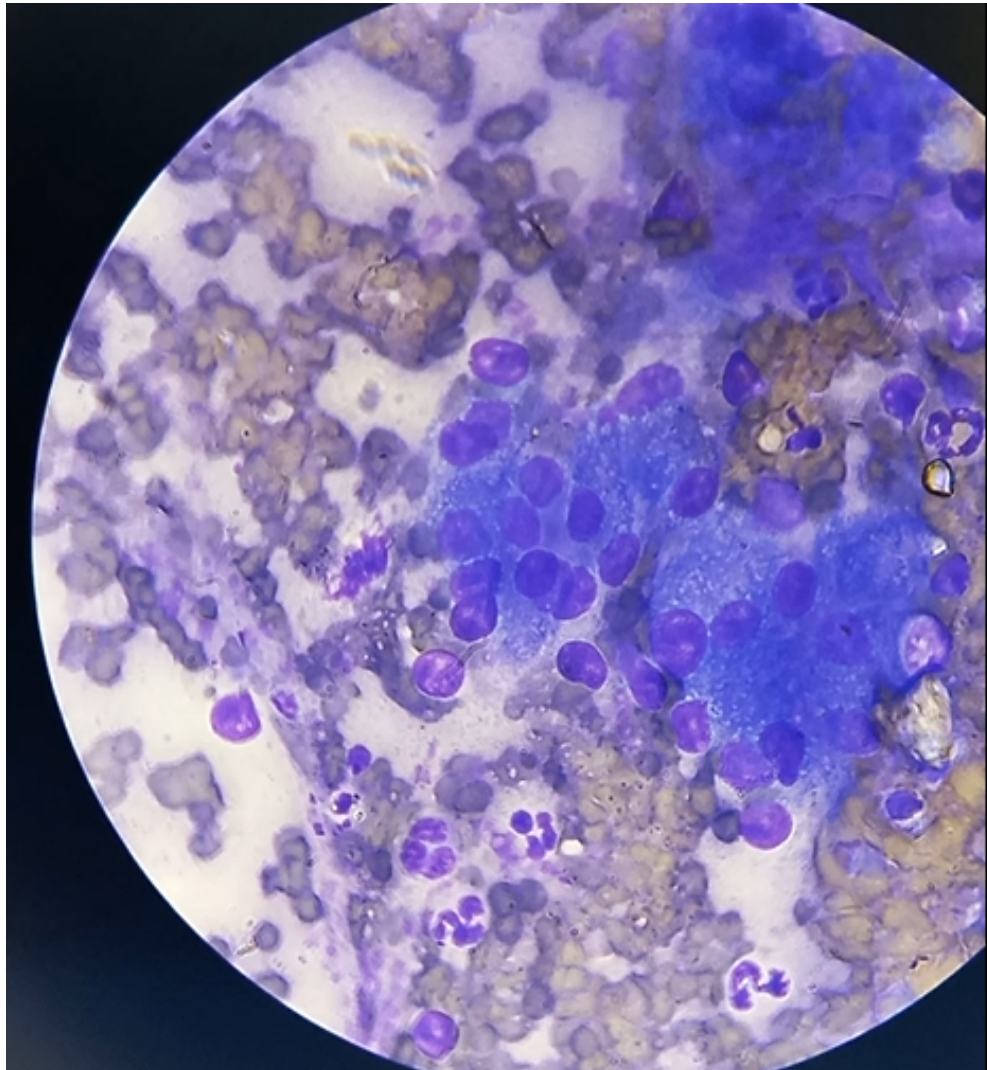


Image shows representative cells collected from the pancreatic nodule in Tommy. Note the vacuolization of the cells and the neutrophils associated with these cells.

HOSPITAL NAME

Central Veterinary
Hospital

The information and recommendations provided are based on the images presented by the referring veterinarian. No evaluation can be communicated regarding pathology that was not visible in the image/video clips provided.

Thank you for this referral. If the clinical or image interpretation does not parallel your findings or if I can be of any further assistance, please contact me.

REFERRING VET

Dr. Anna St. Sir

L.D. McGill, DVM, Ph.D., DACVP
8288 Top of the World Drive
Cottonwood Heights, UT 84121
ldmcgill.vetpath@gmail.com
cell: 801-865-1220

INVOICE NUMBER

40550



DATE

6/21/22

INTERPRETED BY

L.D. McGill, DVM,
Ph.D, DACVP

PATIENT

Tommy Gandy

SPECIES

Feline

BREED

DSH

SEX

Male Neutered

AGE

11y

WEIGHT

13

HOSPITAL NAME

Central Veterinary
Hospital

REFERRING VET

Dr. Anna St. Sir

INVOICE NUMBER

40550