



DATE PRESENTING CLINICAL SIGNS

6/21/22

Increased liver values noted on pre-anesthetic bloodwork for a dental. Patient was treated with Denamarin, Metronidazole and Amoxicillin. At recheck, liver values had continued to increase.
PE: Periodontal disease 2/4, BCS 7/9

INTERPRETED BY

L.D. McGill, DVM,
Ph.D, DACVP

AUS: moderate hepatomegaly with no obvious masses noted.
BW (5/24/22) ALT 213, ALP 1,275
BW (6/14/22) ALT 321, ALP 1,823
Rest of CBC/Chem WNL.

PATIENT CYTOLOGY SUBMISSION

Pogi Avery

FNA of Liver

SPECIES

Canine

OBSERVATIONS

Liver: Submitted are 10 excellent videos of moderate collections of cells from the liver in Pogi. Very few hepatocytes are identified but they are present. This confirms hepatocellular aspiration. The major cellularity includes large numbers of red blood cells and neutrophils. There are lymphocytes and macrophages in the collection. The neutrophils are very prominent and in numbers expected for inflammation. There are no changes to suggest malignancy.

BREED

Pomeranian

INTERPRETATION OF THE FINDINGS & FURTHER RECOMMENDATIONS

Liver - Severe suppurative hepatitis with macrophages and a few lymphocytes.

SEX

Male Neutered

COMMENTS

The changes in this collection are consistent with those of a chronic suppurative inflammatory process in the liver. There are no changes that would suggest malignancy. There are a few reactive lymphoid cells and macrophages. This suggests a pyogranulomatous inflammatory process. All of these changes are consistent with a bacterial infection. I wonder about the possibility of secondary bacterial inflammation from the periodontal disease or possibly secondary to other changes including pancreatitis. Since you were having problems getting hepatocytes, I wonder about fibrosis or chronic liver disease in Pogi. A guarded prognosis is warranted.

AGE

9 years

WEIGHT

27 lbs

HOSPITAL NAME

Scanvet

REFERRING VET

Dr. Kaltsas

INVOICE NUMBER

40549



DATE

6/21/22

INTERPRETED BY

L.D. McGill, DVM,
Ph.D, DACVP

PATIENT

Pogi Avery

SPECIES

Canine

BREED

Pomeranian

SEX

Male Neutered

AGE

9 years

WEIGHT

27 lbs

HOSPITAL NAME

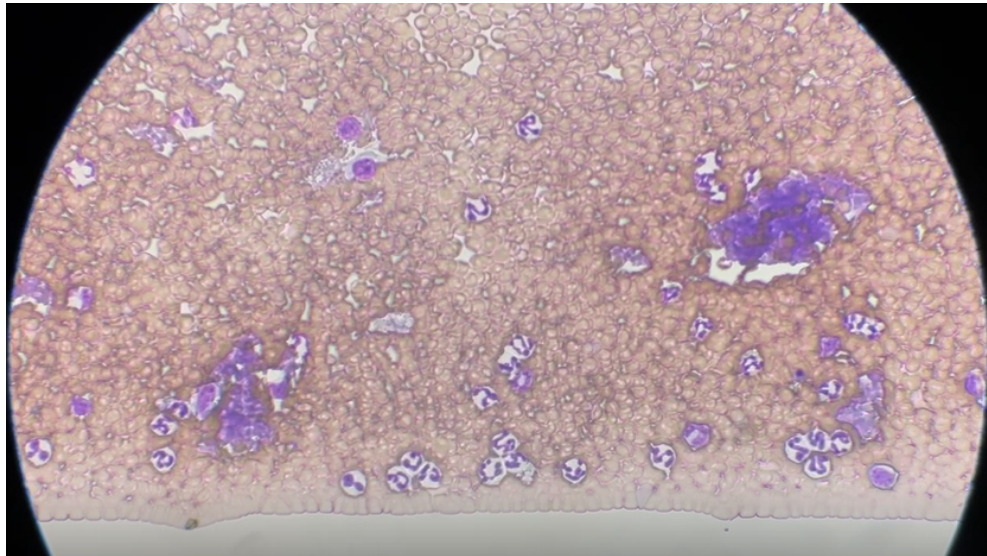
Scanvet

REFERRING VET

Dr. Kaltsas

INVOICE NUMBER

40549



Image

shows large numbers of neutrophils, some macrophages and clumps of platelets collected from the liver in Pogi. There are no hepatocytes in this image, but they were in others.

The information and recommendations provided are based on the images presented by the referring veterinarian. No evaluation can be communicated regarding pathology that was not visible in the image/video clips provided.

Thank you for this referral. If the clinical or image interpretation does not parallel your findings or if I can be of any further assistance, please contact me.

L.D. McGill, DVM, Ph.D., DACVP
8288 Top of the World Drive
Cottonwood Heights, UT 84121
ldmcgill.vetpath@gmail.com
cell: 801-865-1220