



DATE PRESENTING CLINICAL SIGNS

6/18/22

Note cytology on abd fluid cytospun prep and abd lymph node aspirates are pending)
Previously healthy indoor only cat Presented to primary care on 6/6/2022 for lethargy, intermittent vomiting and ptyalism. Was treated with Cerenia, Convenia, prednisone and Panacur. Initially improved at home but as soon as prednisolone taper was started, he declined within 24 hrs and presented on ER with same signs.

INTERPRETED BY

L.D. McGill, DVM,
Ph.D, DACVP

His last dose of prednisone was 2 days ago (5 mg)

PE tonight remarkable for:

- mildly febrile 103
- good coat and body condition

6/6/22:

PATIENT

Monty Williams

Radiographs no obvious obstruction

CBC: (with path review)

- profound leukocytosis 57K
- marked eosinophilia 68%; mature neut 23%, Lymphs 7%, monos 3%
- chem panel remarkable only for elev ALT 244

SPECIES

Feline

Recheck 6/16:

- CBC: total WBC normal 17.5K; eosinophilia 4.5K, reticulocytosis 125K (not anemic);
- Chems: ALT 171; else normal
- FeLV/FIV neg

BREED

DSH

CYTOLOGY SUBMISSION

Lymph node; abdominal fluid

SEX

Male Neutered

OBSERVATIONS

Lymph node: Submitted are 6 excellent videos of excellent collections of cells from the lymph node in Monty. The majority of the cells are round cells with large nuclei. The nuclei are centered in cytoplasm which is bluish gray. The nuclei have prominent nucleoli and prominent chromatin. They are interspersed with scattered eosinophils, rare neutrophils and very few small mature lymphocytes. These large lymphoid cells demonstrate atypical patterns.

AGE

1y

Abdominal fluid: Submitted are 4 excellent videos of excellent collections of concentrated fluid from the abdominal fluid in Monty. The cellularity is mixed throughout all of these fields. Eosinophils and neutrophils are overly represented. Interspersed are scattered reactive mesothelial cells and some irregular lymphoid cells. The lymphoid cells have characteristics that are similar to those in the lymph node collected.

WEIGHT

5.6kg

INTERPRETATION OF THE FINDINGS & FURTHER RECOMMENDATIONS

Lymph node - Large numbers of large lymphoid cells consistent with high-grade lymphoma

Abdominal fluid - Marked accumulations of neutrophils and eosinophils with scattered irregular atypical lymphoid cells.

HOSPITAL NAME

Animal Emergency Care

COMMENTS

The cellularity in the lymph node and in some of the cells in the fluid are very characteristic of a high-grade lymphoma. Immunophenotyping can be undertaken but this may or may not be beneficial in Monty. The eosinophilic infiltration in the fluid and in the lymph node may correlate with a T cell type lymphoma but this would have to be correlated with immunophenotyping. An unfavorable prognosis is warranted in my opinion with this collection and associated with the clinical signs. Chemotherapy may be of benefit in the near term with Monty but long term most likely will result in an unfavorable prognosis particularly with the extensive fluid buildup. FeLV and FIV testing should be undertaken if it has not already been done.

REFERRING VET

Dr. Drummond

INVOICE NUMBER

748



DATE

6/18/22

INTERPRETED BY

L.D. McGill, DVM,
Ph.D, DACVP

PATIENT

Monty Williams

SPECIES

Feline

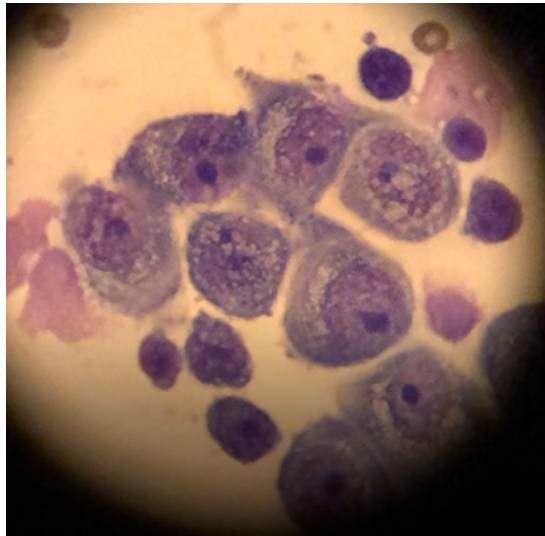


Image shows some of the irregular large lymphoid cells from the lymph node in Monty. Note the prominent nucleoli.

BREED

DSH

SEX

Male Neutered

AGE

1y

WEIGHT

5.6kg

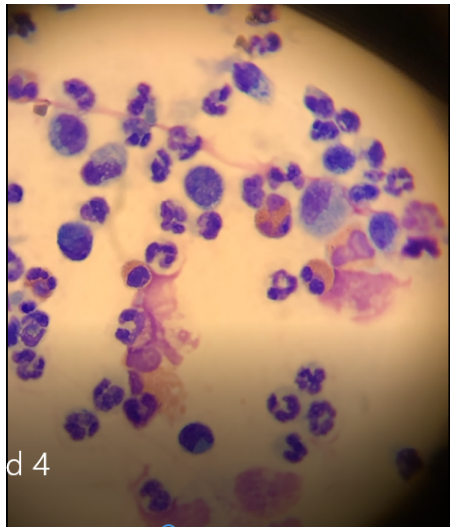


Image shows cells from the abdominal fluid in Monty. There are round cells that have a similar appearance to those in the lymph node. There are prominent eosinophils and neutrophils.

HOSPITAL NAME

Animal Emergency Care

REFERRING VET

Dr. Drummond

The information and recommendations provided are based on the images presented by the referring veterinarian. No evaluation can be communicated regarding pathology that was not visible in the image/video clips provided.

Thank you for this referral. If the clinical or image interpretation does not parallel your findings or if I can be of any further assistance please contact me.

INVOICE NUMBER

748



DATE L.D. McGill, DVM, Ph.D., DACVP

6/18/22
8288 Top of the World Drive
Cottonwood Heights, UT 84121
ldmcgill.vetpath@gmail.com
cell: 801-865-1220

INTERPRETED BY

L.D. McGill, DVM,
Ph.D., DACVP

PATIENT

Monty Williams

SPECIES

Feline

BREED

DSH

SEX

Male Neutered

AGE

1y

WEIGHT

5.6kg

HOSPITAL NAME

Animal Emergency Care

REFERRING VET

Dr. Drummond

INVOICE NUMBER

748