



DATE PRESENTING CLINICAL SIGNS

6/18/22

Previously healthy indoor only cat presented on ER evening of 6/16 for complaint of acute onset repeated intractable vomiting and vocalizing.
PE remarkable for fever 104.8 and profoundly painful abdomen (have started fentanyl CRI)

INTERPRETED BY

L.D. McGill, DVM,
Ph.D, DACVP

Radiographs:
Unremarkable thorax, free abd fluid
Painful abdomen, fever 104;
CBC: neutropenia (0.35K)

PATIENT

Little Bit Everyhope-
Roser

Chems:
-hypophosphatemia 2.0
-hypocalcemia 5.7
-ALT 377
-Lipase >6000

CYTOLOGY SUBMISSION

Abdominal fluid

SPECIES OBSERVATIONS

Feline

Abdominal fluid: Submitted are 5 excellent videos of excellent collections of the concentrated sample of fluid from the abdomen in Littlebit. The cellularity consists of large numbers of neutrophils with rare eosinophils. There are good numbers of macrophages interspersed, many of which contain hemosiderin. Red blood cells are prominent throughout the fields. Scattered reactive mesothelial cells are identified. The majority of those cells and macrophages contain hemosiderin.

BREED

DSH

INTERPRETATION OF THE FINDINGS & FURTHER RECOMMENDATIONS

Abdominal fluid - Chronic hemorrhagic and suppurative peritonitis with hemosiderin laden macrophages

SEX

Female Spayed

COMMENTS

The red blood cells and hemosiderin strongly support the likelihood of a hemorrhagic abdominal inflammatory process with secondary inflammation. This could be secondary to pancreatitis or other abnormalities in the abdominal cavity. Malignant cellularity is not identified in this collection. Exploratory and treatment for inflammation can be considered. The changes in the cells in this collection are chronic in nature and demonstrate a rather severe process in the abdominal cavity. A guarded to unfavorable prognosis is certainly warranted.

AGE

6y

WEIGHT

5kg

HOSPITAL NAME

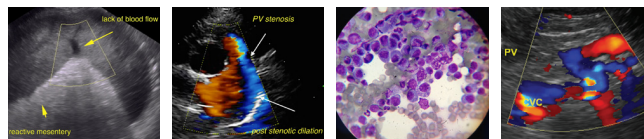
Animal Emergency Care

REFERRING VET

Dr. Drummond

INVOICE NUMBER

749



DATE

6/18/22

INTERPRETED BY

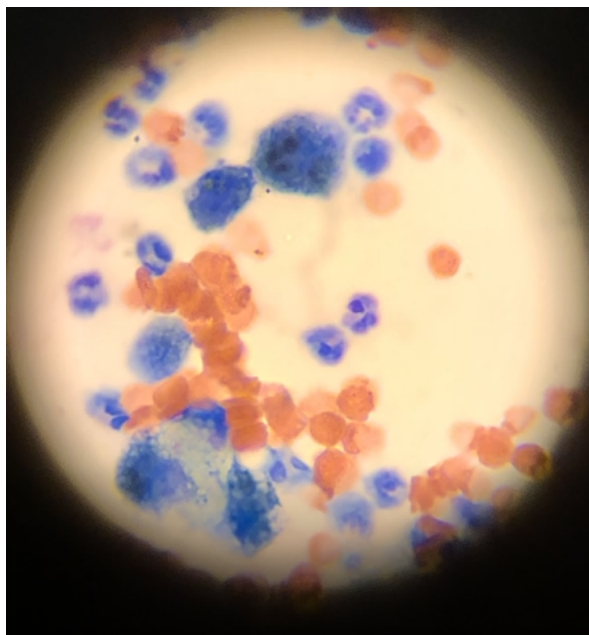
L.D. McGill, DVM,
Ph.D, DACVP

PATIENT

Little Bit Everyhope-
Roser

SPECIES

Feline



BREED

DSH

SEX

Female Spayed

The information and recommendations provided are based on the images presented by the referring veterinarian. No evaluation can be communicated regarding pathology that was not visible in the image/video clips provided.

AGE

6y

Thank you for this referral. If the clinical or image interpretation does not parallel your findings or if I can be of any further assistance please contact me.

WEIGHT

5kg

L.D. McGill, DVM, Ph.D., DACVP
8288 Top of the World Drive
Cottonwood Heights, UT 84121
ldmcgill.vetpath@gmail.com
cell: 801-865-1220

HOSPITAL NAME

Animal Emergency Care

REFERRING VET

Dr. Drummond

INVOICE NUMBER

749