



**DATE PRESENTING CLINICAL SIGNS**

6/18/22

Enlarged spleen, noticed 6 months ago, slowly growing. Came in for routine ultrasound, single, hypoechoic nodule (1.8cm) found, ultrasound guided FNA done.

**CYTOLOGY SUBMISSION**

**INTERPRETED BY**

Spleen

L.D. McGill, DVM,  
Ph.D, DACVP

**OBSERVATIONS**

Spleen: Submitted are 5 excellent videos of excellent collections of cells from the spleen in Jojo. The cellularity consists mainly of round cells. The majority of the round cells are small mature lymphocytes. Scattered larger lymphoid cells are identified as are macrophages and neutrophils. The small mature lymphocytes are approximately 70% of the cellularity. There were fields with nucleated RBCs.

**PATIENT**

Jojo Bartlett

**INTERPRETATION OF THE FINDINGS & FURTHER RECOMMENDATIONS**

Spleen - Large numbers of small lymphocytes consistent with lymphocytic nodular hyperplasia in the spleen.

**SPECIES**

Canine

**COMMENTS**

The cellularity supports a lymphocytic infiltration in a localized area in the spleen. This is a common lesion in the spleen which is a benign accumulation of small mature lymphocytes. Malignant characteristics were not confirmed. There are some cases where small cell lymphoma could have this appearance but I do not expect that to be the case. Immunophenotyping the cells will likely rule out the possibility of neoplasia. These types of reaction can occur as a result of inflammation in other organs in the abdominal cavity or as a systemic inflammatory process with local lymphoid stimulation in the spleen. If the lesions become large enough, excision may be required due to the mechanical interference in the abdomen. At this time, I would recommend a favorable prognosis but monitoring is certainly in order.

**BREED**

Hound Cross

**SEX**

Female Spayed

**AGE**

9y

**WEIGHT**

58.8

**HOSPITAL NAME**

Rotterdam Veterinary  
Hospital

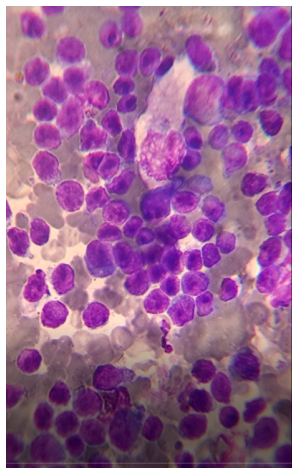


Image shows a representative collection of small to intermediate sized lymphocytes from the splenic nodule in Jojo. Small lymphocytes are prominent.

**REFERRING VET**

Dr. Anna St Sir

The information and recommendations provided are based on the images presented by the referring veterinarian. No evaluation can be communicated regarding pathology that was not visible in the image/video clips provided.

**INVOICE NUMBER**

747



**DATE** 6/18/22 Thank you for this referral. If the clinical or image interpretation does not parallel your findings or if I can be of any further assistance please contact me.

**INTERPRETED BY** L.D. McGill, DVM, Ph.D., DACVP  
8288 Top of the World Drive  
Cottonwood Heights, UT 84121  
ldmcgill.vetpath@gmail.com  
cell: 801-865-1220

**PATIENT**  
Jojo Bartlett

**SPECIES**  
Canine

**BREED**  
Hound Cross

**SEX**  
Female Spayed

**AGE**  
9y

**WEIGHT**  
58.8

**HOSPITAL NAME**  
Rotterdam Veterinary  
Hospital

**REFERRING VET**  
Dr. Anna St Sir

**INVOICE NUMBER**  
747