



DATE PRESENTING CLINICAL SIGNS

6/17/22

The spleen was enlarged with scalloping contour and measured 1.4 cm. A mild amount of free fluid was noted likely owing to lymphatic obstruction

INTERPRETED BY CYTOLOGY SUBMISSION

L.D. McGill, DVM,
Ph.D, DACVP

FNA of Spleen

PATIENT

Jackson Riverson

OBSERVATIONS

Spleen: Submitted are 4 excellent videos of excellent collections of cells from the spleen in Jackson. The cellularity is demonstrating high numbers of round cells. The round cells have minimal cytoplasm. The nuclei are 2 to 4 times the size of red blood cells and occasionally up to 6 times the size of red blood cells. Occasional cells have nucleoli. There are scattered neutrophils, eosinophils and plasma cells in the collection. The lymphoid cellularity is rather uniform.

INTERPRETATION OF THE FINDINGS & FURTHER RECOMMENDATIONS

SPECIES

Feline

Spleen - Consistent with intermediate to high-grade lymphoma of the spleen.

BREED

DSH

COMMENTS

The cellularity strongly supports lymphoma. The cellularity does not appear to be high-grade but it is certainly very suggestive of low-grade. The cellularity is so uniform that neoplasia has to be at the top of the list. There is mild inflammation. Splenectomy may be beneficial in Jackson since some cases of lymphoma can be limited to that organ. Immunophenotyping the cells could possibly be beneficial in prognosis but, immunophenotyping is not as beneficial in the cat as in the dog. An unfavorable prognosis is warranted in my opinion.

SEX

Male Neutered

AGE

14yr

WEIGHT

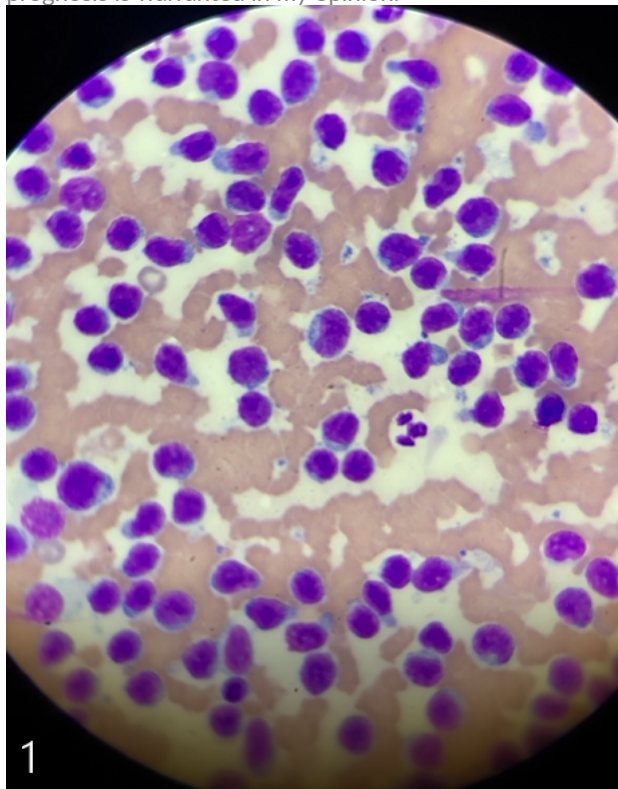
13#

HOSPITAL NAME

Rockaway Animal
Hospital

REFERRING VET

Dr. Maniar



INVOICE NUMBER

40547

Image demonstrates a representative cellular collection from the spleen in Jackson. Note the uniform large lymphoid cells as compared to the neutrophil.



DATE

6/17/22

The information and recommendations provided are based on the images presented by the referring veterinarian. No evaluation can be communicated regarding pathology that was not visible in the image/video clips provided.

INTERPRETED BY

L.D. McGill, DVM,
Ph.D, DACVP

Thank you for this referral. If the clinical or image interpretation does not parallel your findings or if I can be of any further assistance, please contact me.

PATIENT

Jackson Riverson

L.D. McGill, DVM, Ph.D., DACVP
8288 Top of the World Drive
Cottonwood Heights, UT 84121
ldmcgill.vetpath@gmail.com
cell: 801-865-1220

SPECIES

Feline

BREED

DSH

SEX

Male Neutered

AGE

14yr

WEIGHT

13#

HOSPITAL NAME

Rockaway Animal
Hospital

REFERRING VET

Dr. Maniar

INVOICE NUMBER

40547