



DATE PRESENTING CLINICAL SIGNS

6/17/22

P hx-Diarrhea U/S Findings: The spleen was mildly enlarged with uniform, but subtly micronodular parenchyma, and undulating capsular contour

INTERPRETED BY CYTOLOGY SUBMISSION

L.D. McGill, DVM,
Ph.D, DACVP

Spleen

OBSERVATIONS

Spleen: Submitted are 3 excellent videos of minimal to moderate cellularity from the spleen in Elton. The cellularity is mixed with nucleated red blood cells, scattered neutrophils, lymphocytes, and packets of fibrosis with macrophages. Some of the cells are undergoing degeneration. Malignant characteristics are not identified. There is mild inflammation.

PATIENT

Elton Tourne

INTERPRETATION OF THE FINDINGS & FURTHER RECOMMENDATIONS

Spleen - Fibrohistiocytic nodules with mixed cell collection and mild inflammation.

SPECIES

Feline

COMMENTS

The cellularity in this collection is not specific for any process. There are no changes that would suggest malignancy. The changes are most consistent with those of chronic inflammation and chronic irritation to the spleen. This can occur secondarily as a result of problems in the intestine or the pancreas. Pancreatitis can result in this type of change. Other inflammatory processes in the abdominal cavity might respond with this type of change. Malignancy or sepsis are not identified. These changes are not classical for feline infectious peritonitis. A guarded prognosis is warranted since the spleen is likely responding secondarily.

BREED

DSH

SEX

Male Neutered

AGE

6y

WEIGHT

14.5#

HOSPITAL NAME

Rockaway Animal
Hospital

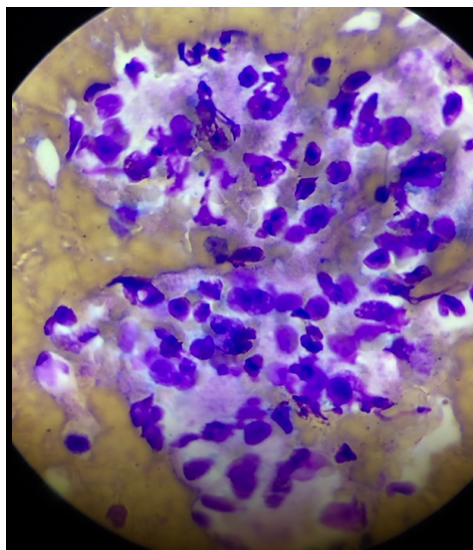


Image shows cells from a potential fibrohistiocytic nodule. There is a mixture of cells in this aggregation.

REFERRING VET

Dr. Maniar

The information and recommendations provided are based on the images presented by the referring veterinarian. No evaluation can be communicated regarding pathology that was not visible in the image/video clips provided.

INVOICE NUMBER

745



DATE 6/17/22 Thank you for this referral. If the clinical or image interpretation does not parallel your findings or if I can be of any further assistance please contact me.

INTERPRETED BY L.D. McGill, DVM, Ph.D., DACVP
8288 Top of the World Drive
Cottonwood Heights, UT 84121
ldmcgill.vetpath@gmail.com
cell: 801-865-1220

PATIENT
Elton Tourne

SPECIES
Feline

BREED
DSH

SEX
Male Neutered

AGE
6y

WEIGHT
14.5#

HOSPITAL NAME
Rockaway Animal
Hospital

REFERRING VET
Dr. Maniar

INVOICE NUMBER
745