



DATE PRESENTING CLINICAL SIGNS

6/16/2023

Mild anemia, slightly larger kidneys, losing weight. during last PE on 5/11/23

CYTOLOGY SUBMISSION

Lymph node

INTERPRETED BY

L.D. McGill, DVM,
Ph.D, DACVP

OBSERVATIONS

Lymph node: Submitted are 5 excellent videos of excellent collections of cells from the mesenteric lymph node in Willow. The cellularity consists of large numbers of lymphoid cells the majority of which are small to intermediate. There are scattered enlarged cells but they are few and numbers. There are scattered eosinophils and neutrophils. The cellularity is mainly that of a reactive lymph node.

PATIENT

Willow Gingell

INTERPRETATION OF THE FINDINGS & FURTHER RECOMMENDATIONS

Lymph node - Consistent with reactive or stimulated lymph node with mild eosinophilic inflammation.

COMMENTS

SPECIES

Feline

The cellularity in the collection supports a reactive lymph node with large numbers of small lymphocytes. There are scattered large lymphocytes but they are few in number. There is inadequate cellularity of an atypical nature to support lymphoma. No other specific cellular change is identified except for the eosinophils and rare neutrophils. This supports a reactive lymph node with inflammation. The source of this inflammatory process is not identified. A guarded prognosis is warranted since the underlying process is not included in this collection. The lymph node is likely involved secondarily. There can be lymphoma in the intestinal tissue which would not affect the regional lymph node. This is due to the fact that the lymphoid tissue in the intestine has specific markers to only grow in the intestine and not in the regional lymph node. Continued evaluation for problems in other organs in the abdominal cavity is encouraged.

BREED

DLH

SEX

Female Spayed

AGE

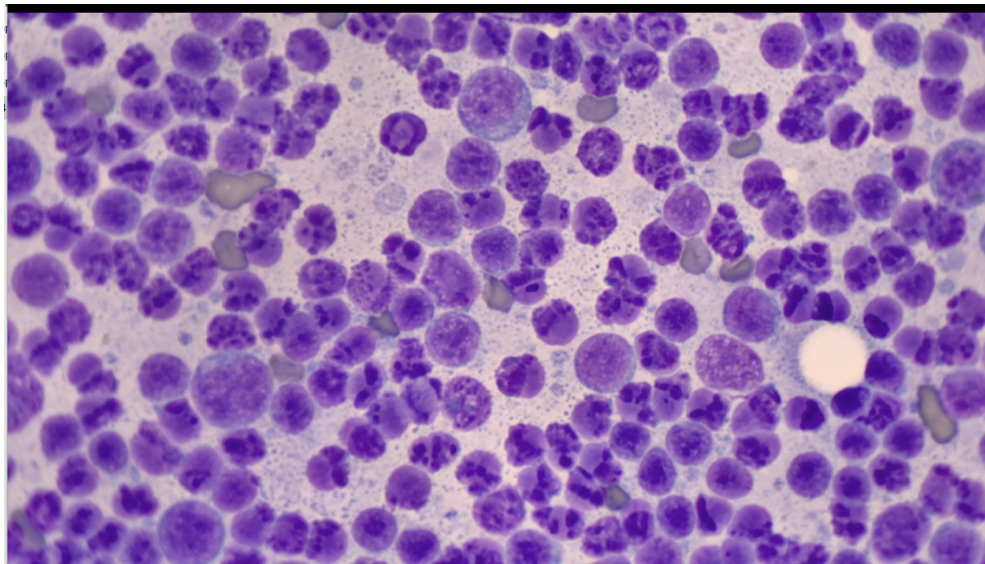
18

WEIGHT

10.4

HOSPITAL NAME

Rotterdam Veterinary
Hospital



REFERRING VET

Dr. St. Sir

Image shows a good collection of lymphoid cells collected from the mesenteric lymph node in Willow. Note the large number of small lymphocytes. There are large lymphoid cells but they are few in numbers.

INVOICE NUMBER

968



DATE

6/16/2023

The information and recommendations provided are based on the images presented by the referring veterinarian. No evaluation can be communicated regarding pathology that was not visible in the image/video clips provided.

INTERPRETED BY

L.D. McGill, DVM,
Ph.D., DACVP

Thank you for this referral. If the clinical or image interpretation does not parallel your findings or if I can be of any further assistance please contact me.

L.D. McGill, DVM, Ph.D., DACVP
8288 Top of the World Drive
Cottonwood Heights, UT 84121
ldmcgill.vetpath@gmail.com
cell: 801-865-1220

PATIENT

Willow Gingell

SPECIES

Feline

BREED

DLH

SEX

Female Spayed

AGE

18

WEIGHT

10.4

HOSPITAL NAME

Rotterdam Veterinary
Hospital

REFERRING VET

Dr. St. Sir

INVOICE NUMBER

968