



DATE PRESENTING CLINICAL SIGNS

6/15/22 Owner brought in for excessive drooling and not eating, pawing at face. Upon exam Right underside of tongue has a smooth, red swelling along length. Tongue is deviated to Left. Painful.

INTERPRETED BY CYTOLOGY SUBMISSION

L.D. McGill, DVM,
Ph.D, DACVP

FNA of Lesion under the tongue

PATIENT OBSERVATIONS

Baxter Smith

Lesion under the tongue: Submitted are 4 excellent videos of excellent collections of cells from the location under the tongue on Baxter. The cellularity is consistent with aggregated cells with anisocytosis and anisokaryosis. The cells have fairly prominent nucleoli. There are scattered neutrophils throughout the tissue aggregates. The cytoplasm is difficult to identify in many of the cells. This suggests a proliferative epithelial process.

SPECIES

Feline

INTERPRETATION OF THE FINDINGS & FURTHER RECOMMENDATIONS

Lesion under the tongue - Epithelial cell proliferation consistent with squamous cell carcinoma.

BREED

DSH

COMMENTS

The changes are suggestive of an early high-grade lymphoma. This could be derived from many The cellularity strongly suggests the likelihood of a squamous cell carcinoma. The cellularity is very aggressive with the packeting and solid patterns of growth. There is inflammation which is common with this type of tumor. This is an area which will be difficult to excise the mass. Treatment will be difficult. You may consider radiation or chemotherapy. Oncology consultation may be beneficial if therapy is considered.

SEX

Male Neutered

AGE

13y

WEIGHT

9.8lbs

HOSPITAL NAME

Rotterdam Veterinary
Hospital

REFERRING VET

Dr. Anna St Sir

INVOICE NUMBER

40545



DATE

6/15/22

INTERPRETED BY

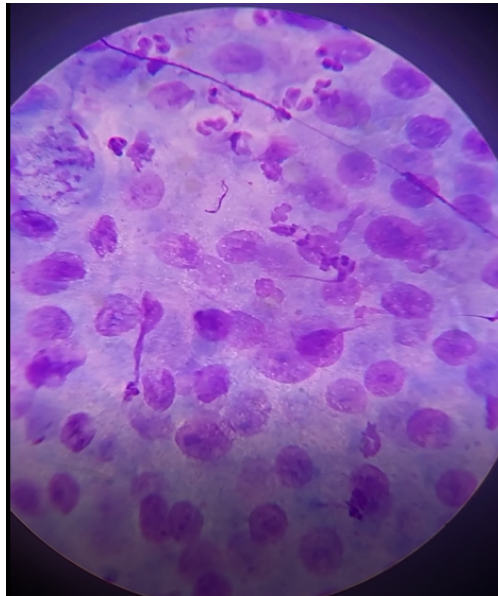
L.D. McGill, DVM,
Ph.D, DACVP

PATIENT

Baxter Smith

SPECIES

Feline



BREED

DSH

The information and recommendations provided are based on the images presented by the referring veterinarian. No evaluation can be communicated regarding pathology that was not visible in the image/video clips provided.

SEX

Male Neutered

Thank you for this referral. If the clinical or image interpretation does not parallel your findings or if I can be of any further assistance, please contact me.

AGE

13y

L.D. McGill, DVM, Ph.D., DACVP
8288 Top of the World Drive
Cottonwood Heights, UT 84121
ldmcgill.vetpath@gmail.com
cell: 801-865-1220

WEIGHT

9.8lbs

HOSPITAL NAME

Rotterdam Veterinary
Hospital

REFERRING VET

Dr. Anna St Sir

INVOICE NUMBER

40545