



DATE PRESENTING CLINICAL SIGNS

6/14/22 Presented for routine cleaning and found mass on preop exam. Mass is on the medial aspect of the 2nd digit right pelvic limb. Lesion is raised, pink, firm, about 7 mm diameter, granular surface. Histiocytoma is suspected.

INTERPRETED BY CYTOLOGY SUBMISSION

Skin lesion

L.D. McGill, DVM,
Ph.D, DACVP

OBSERVATIONS

Skin mass: Submitted are 5 excellent videos of excellent collections of cells from skin mass on Mollie. The cellularity consists of a uniform cellularity of round cells with prominent nuclei that are centrally located. Many of the cells have a fried egg pattern. This is a common pattern for histiocytoma cells. There are scattered lymphocytes in the collection but they are few in numbers.

PATIENT

Mollie Apel

INTERPRETATION OF THE FINDINGS & FURTHER RECOMMENDATIONS

Skin mass - Histiocytoma.

SPECIES

Canine

COMMENTS

This is an excellent collection of cellularity from this skin mass in Mollie. The cellularity is characteristic of a histiocytoma and localized round cell tumor. As you well know these lesions often regress on their own. A favorable prognosis is expected. Even this aspiration may be beneficial in treatment. No other significant cellularity is identified. Again this is an excellent collection and a favorable prognosis is expected.

BREED

Mix

SEX

Female spayed

AGE

9y

WEIGHT

27 lbs

HOSPITAL NAME

Friendship Springs
Veterinary Care

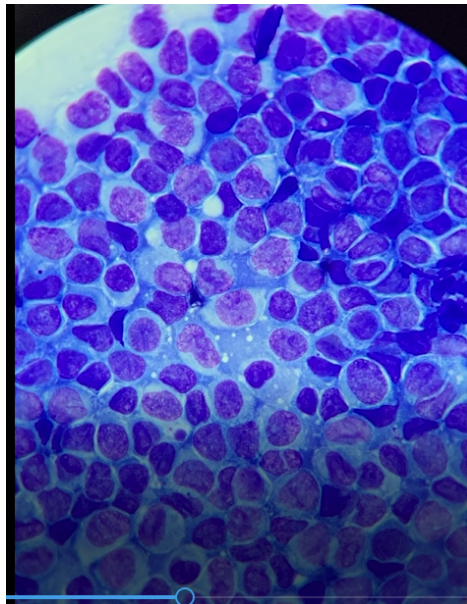


Image shows a good number of cells collected from the skin mass on Mollie. Excellent collection.

REFERRING VET

Dr. Cutchin

The information and recommendations provided are based on the images presented by the referring veterinarian. No evaluation can be communicated regarding pathology that was not visible in the image/video clips provided.

INVOICE NUMBER

742



DATE Thank you for this referral. If the clinical or image interpretation does not parallel your findings or if I can be of any further assistance please contact me.

6/14/22

INTERPRETED BY L.D. McGill, DVM, Ph.D., DACVP
8288 Top of the World Drive
Cottonwood Heights, UT 84121
ldmcgill.vetpath@gmail.com
cell: 801-865-1220

PATIENT

Mollie Apel

SPECIES

Canine

BREED

Mix

SEX

Female spayed

AGE

9y

WEIGHT

27 lbs

HOSPITAL NAME

Friendship Springs
Veterinary Care

REFERRING VET

Dr. Cutchin

INVOICE NUMBER

742