



DATE PRESENTING CLINICAL SIGNS

6/14/22

Pet came in for vomiting. On the abdominal ultrasound section of the small intestine had severely thickened (up to 1.8 cm) hypochoic walls with loss of normal layering. Mesenteric lymph nodes - slightly enlarged (0.6 cm thickness), hypochoic with hyperechoic surrounding mesentery. Spleen - slightly enlarged (1 cm thickness), smooth. U/S-guided FNA of the intestinal wall is submitted in this sample.

INTERPRETED BY

L.D. McGill, DVM,
Ph.D, DACVP

Vomiting, palpable intestinal mass, BW - NSF.

PATIENT CYTOLOGY SUBMISSION

Isabelle Allmond

FNA of Spleen

OBSERVATIONS

SPECIES

Feline

Spleen: Submitted are 4 excellent videos of slightly out of focus images of cells collected from the spleen in Isabelle. The cellularity is mixed with neutrophils and lymphocytes. There are several fields of smudge cells with scattered degenerate debris. Malignant characteristics cannot be confirmed. There is mild information.

BREED

DSH

INTERPRETATION OF THE FINDINGS & FURTHER RECOMMENDATIONS

Spleen - Consistent with splenitis with no significant evidence of neoplasia.

SEX

Female, Spayed

COMMENTS

The cellularity in the spleen is not diagnostic of lymphoma. Lymphoma could be present, but cellularity is not characteristic. There is evidence of mild inflammation. Intestinal lymphoma often does not affect other organs in the abdominal cavity. There are markers in the lymphoma cells that make them grow only in the intestine. An unfavorable prognosis is warranted in Isabelle.

AGE

06-03-2013

WEIGHT

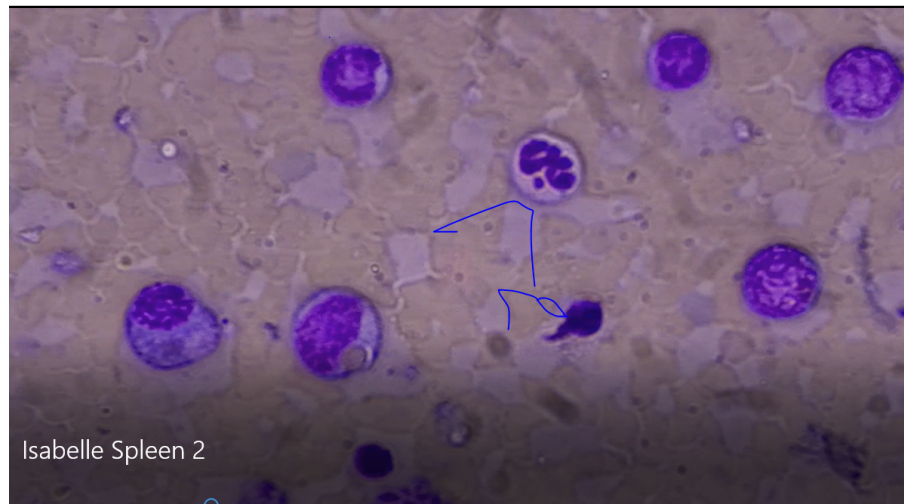
10

HOSPITAL NAME

Central Veterinary
Hospital

REFERRING VET

Dr. Anna St. Sir



Isabelle Spleen 2

Image shows some of the cells collected from the spleen in Isabelle. Sorry for the lines. They are pointing to a neutrophil and degenerate cell.

INVOICE NUMBER

40544



DATE 6/14/22 The information and recommendations provided are based on the images presented by the referring veterinarian. No evaluation can be communicated regarding pathology that was not visible in the image/video clips provided.

INTERPRETED BY L.D. McGill, DVM, Ph.D., DACVP Thank you for this referral. If the clinical or image interpretation does not parallel your findings or if I can be of any further assistance, please contact me.

L.D. McGill, DVM,
Ph.D., DACVP

L.D. McGill, DVM, Ph.D., DACVP
8288 Top of the World Drive
Cottonwood Heights, UT 84121
ldmcgill.vetpath@gmail.com
cell: 801-865-1220

PATIENT

Isabelle Allmond

SPECIES

Feline

BREED

DSH

SEX

Female, Spayed

AGE

06-03-2013

WEIGHT

10

HOSPITAL NAME

Central Veterinary
Hospital

REFERRING VET

Dr. Anna St. Sir

INVOICE NUMBER

40544