



DATE PRESENTING CLINICAL SIGNS

6/13/23

Weight loss with increased appetite, diarrhea. On abdominal ultrasound - enlarged spleen, enlarged coarse liver, enlarged mesenteric lymph nodes with hyperechoic mesentery around. Slightly elevated fPL

INTERPRETED BY

L.D. McGill, DVM,
Ph.D, DACVP

CYTOLOGY SUBMISSION

FNA of Spleen

PATIENT

Optimus Prime Pryor

OBSERVATIONS

Spleen: Submitted are 7 excellent videos of excellent collections of cells from the spleen. Some of the collections are quite dense and uninterpretable. There are adequate collections that include round cells that are characteristic of lymphoid cells. They have large irregular nuclei with prominent nucleoli. The cytoplasm is minimal. The cytoplasm and cellular collections are slightly irregular. There are places where the cells are aggregated with platelets. There are a few neutrophils scattered throughout. Some of the lymphoid cells have cleaved nuclei. Scattered eosinophils are observed.

SPECIES

feline

BREED

DSH

INTERPRETATION OF THE FINDINGS & FURTHER RECOMMENDATIONS

Spleen - Increased numbers of lymphoid cells suggestive of an intermediate lymphoma with mild inflammation.

SEX

Male Neutered

COMMENTS

AGE

11 y/o

The cellularity in this spleen suggests the likelihood of a lymphoma which is similar to the cellularity in the liver. At this time the cellularity is not diagnostic, but it is strongly suggestive. Immunophenotyping the cells from the spleen would be encouraged since there are large numbers of cells present in the spleen. Immunophenotyping will hopefully confirm whether this is lymphoma or not. A lymphoid inflammatory process is possible but there is not as much inflammation as I would expect for that type of disease process. A guarded to unfavorable prognosis is warranted since there are still questions as to what may be occurring in Optimus Prime.

WEIGHT

13.6 lb

HOSPITAL NAME

Central Veterinary
Hospital

REFERRING VET

Dr. Anna St. Sir

INVOICE NUMBER

40758



DATE

6/13/23

INTERPRETED BY

L.D. McGill, DVM,
Ph.D., DACVP

PATIENT

Optimus Prime Pryor

SPECIES

feline

BREED

DSH

SEX

Male Neutered

AGE

11 y/o

WEIGHT

13.6 lb

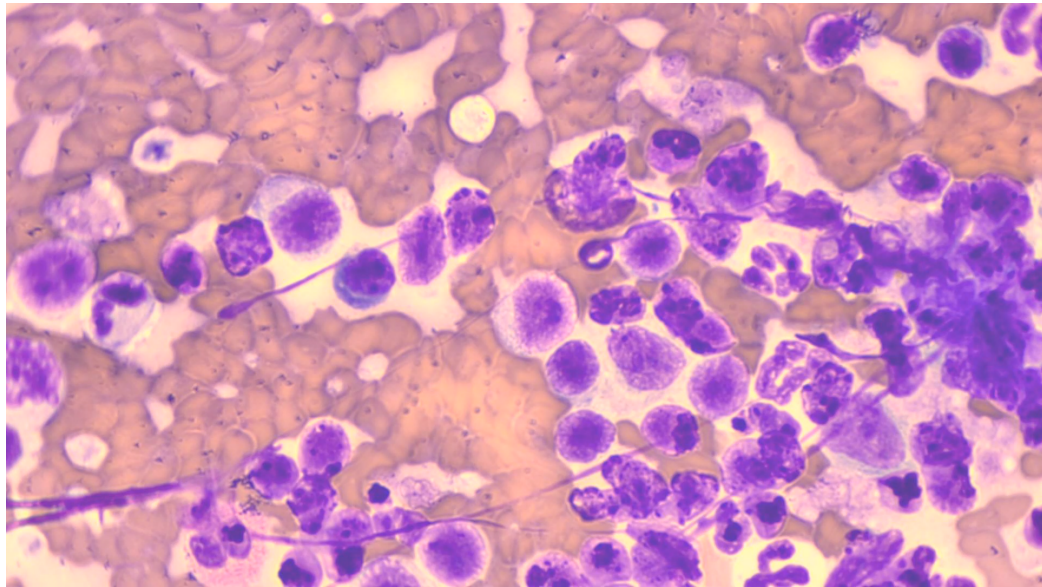


Image shows a group of identifiable lymphoid cells, many of which are large lymphoid cells collected from the spleen in Optimus Pryor. There are prominent and multiple nucleoli in some of the cells. There are scattered neutrophils and small lymphocytes with which to compare the larger lymphoid cells.

The information and recommendations provided are based on the images presented by the referring veterinarian. No evaluation can be communicated regarding pathology that was not visible in the image/video clips provided.

Thank you for this referral. If the clinical or image interpretation does not parallel your findings or if I can be of any further assistance, please contact me.

L.D. McGill, DVM, Ph.D., DACVP
8288 Top of the World Drive
Cottonwood Heights, UT 84121
ldmcgill.vetpath@gmail.com
cell: 801-865-1220

HOSPITAL NAME

Central Veterinary
Hospital

REFERRING VET

Dr. Anna St. Sir

INVOICE NUMBER

40758