



**DATE PRESENTING CLINICAL SIGNS**

6/13/23

Weight loss with increased appetite, diarrhea. On abdominal ultrasound - enlarged spleen, enlarged coarse liver, enlarged mesenteric lymph nodes with hyperechoic mesentery around. Slightly elevated fPL

**INTERPRETED BY**

L.D. McGill, DVM,  
Ph.D, DACVP

**CYTOLOGY SUBMISSION**

FNA of mesenteric lymph nodes.

**PATIENT**

Optimus Prime Pryor

**OBSERVATIONS**

Lymph node: Submitted are 11 excellent videos of very good collections of cells from the mesenteric lymph node in Optimus Prime. There are large numbers of round cells throughout the collection and in many locations they are aggregated. When individualized, they are characteristic of lymphoid cells with a rather uniform appearance. They have some cytoplasm with uniform size of nuclei.

**SPECIES**

feline

Occasionally the nuclei are large. Some of the cells have nucleoli. There is prominent ultrasound gel throughout the collection. RBCs are present in the background.

**BREED**

DSH

**INTERPRETATION OF THE FINDINGS & FURTHER RECOMMENDATIONS**

Lymph node - Large numbers of lymphoid cells with probable reactive lymphoid tissue or possible lymphoma.

**SEX**

Male Neutered

**COMMENTS**

This lymph node is filled with lymphoid cells that are rather uniform throughout the collection. These cells have some of the same appearance as those in the liver and spleen. This could be a lymphoma, but it could also be due to the reactive lymphoid tissue. There were very few neutrophils in the collection. Ultrasound gel is interspersed with some of the cells throughout this collection. Again, immunophenotyping the cells may be beneficial if further diagnostic requirements are needed particularly if there is going to be some therapy. This will assist in confirming whether these cells are neoplastic or not. A guarded to unfavorable prognosis is still warranted since this type of process in both the liver spleen and lymph node could possibly be secondary to pancreatitis or lymphoma.

**AGE**

11 y/o

**WEIGHT**

13.6 lb

**HOSPITAL NAME**

Central Veterinary  
Hospital

**REFERRING VET**

Dr. Anna St. Sir

**INVOICE NUMBER**

40757



**DATE**

6/13/23

**INTERPRETED BY**

L.D. McGill, DVM,  
Ph.D, DACVP

**PATIENT**

Optimus Prime Pryor

**SPECIES**

feline

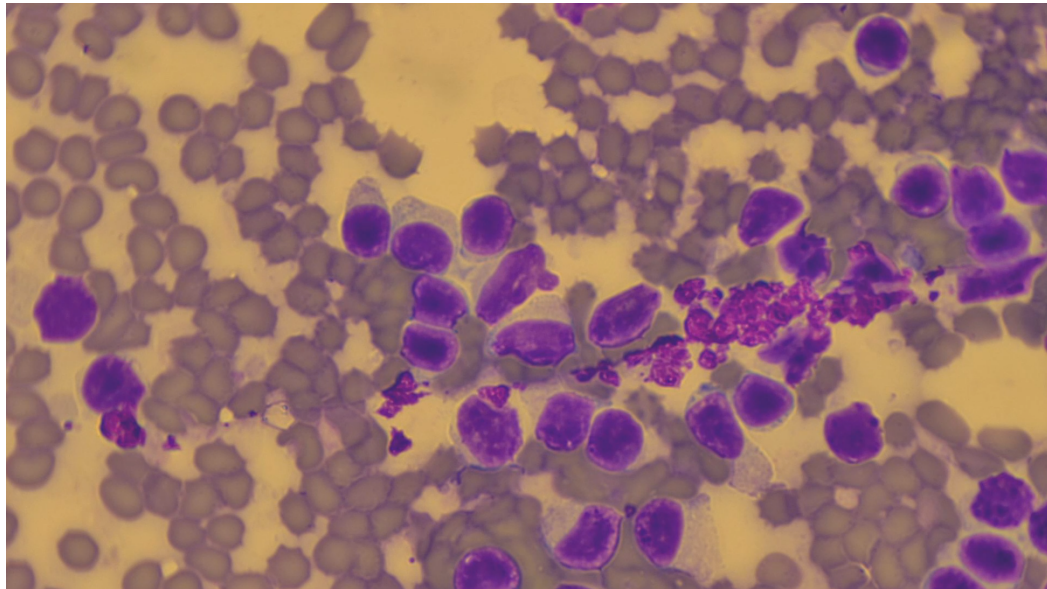


Image shows a group of lymphoid cells collected from the mesenteric lymph node in Optimus Prime. The amorphous purple to pink material adjacent to the right of center is ultrasound gel.

**BREED**

DSH

**SEX**

Male Neutered

**AGE**

11 y/o

**WEIGHT**

13.6 lb

The information and recommendations provided are based on the images presented by the referring veterinarian. No evaluation can be communicated regarding pathology that was not visible in the image/video clips provided.

Thank you for this referral. If the clinical or image interpretation does not parallel your findings or if I can be of any further assistance, please contact me.

L.D. McGill, DVM, Ph.D., DACVP  
8288 Top of the World Drive  
Cottonwood Heights, UT 84121  
ldmcgill.vetpath@gmail.com  
cell: 801-865-1220

**HOSPITAL NAME**

Central Veterinary  
Hospital

**REFERRING VET**

Dr. Anna St. Sir

**INVOICE NUMBER**

40757