



DATE PRESENTING CLINICAL SIGNS

6/13/22

Patient has a history of a chronic wound on the right side of neck. Started in October of 2021, resolved, reoccurred May of 2022. Wound has been as large as 3cm, now 1cm in size. Patient now has swelling at caudal aspect of wound, Swelling, along mandible extending cranially. Firm mass felt in the area under skin which may be a lymph node, but seems too lateral. Aspirates of mass attached.

INTERPRETED BY

L.D. McGill, DVM,
Ph.D, DACVP

CYTOLOGY SUBMISSION

FNA of Skin lesion

PATIENT

Tommy Doran

OBSERVATIONS

Skin lesion: Submitted are 2 excellent videos of excellent collections of cells from the neck skin mass on Tommy. The cellularity is consistent throughout both of these videos. The majority of the cells are round cells with round nuclei. There are scattered enlarged round cells. There are scattered neutrophils in the collection. The majority of the cells are small mature round cells that are mature lymphocytes. Atypical lymphoid cells are few in numbers.

SPECIES

Feline

INTERPRETATION OF THE FINDINGS & FURTHER RECOMMENDATIONS

BREED

Skin lesion - Large numbers of mature lymphoid cells consistent with cutaneous lymphocytosis or early small to intermediate cell cutaneous lymphoma.

DSH

COMMENTS

SEX

Male Neutered

The cellularity supports a proliferation of large numbers of mature lymphocytes. There are scattered reactive lymphoid cells and neutrophils. This type of cellularity can occur with cutaneous lymphocytosis which is a specific process in the cat. It can also be the result of early small cell lymphoma. If confirmation of a diagnosis of lymphoma is required, then immunophenotyping the cells is encouraged. A guarded prognosis is warranted in light of this cellularity. Excision of the mass and follow-up biopsy may also be beneficial in confirming the diagnosis.

AGE

12y

WEIGHT

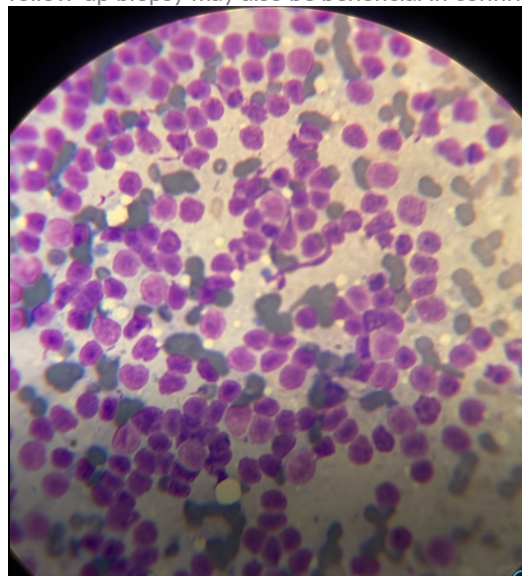
9.7#

HOSPITAL NAME

Rotterdam Veterinary
Hospital

REFERRING VET

Dr. Amy Scarpinato



INVOICE NUMBER

40541

Image shows a representative field of lymphoid cells collected from the skin lesion on Tommy. There are a few large irregular lymphoid cells. This is an excellent collection.



DATE

6/13/22

The information and recommendations provided are based on the images presented by the referring veterinarian. No evaluation can be communicated regarding pathology that was not visible in the image/video clips provided.

INTERPRETED BY

L.D. McGill, DVM,
Ph.D., DACVP

Thank you for this referral. If the clinical or image interpretation does not parallel your findings or if I can be of any further assistance, please contact me.

PATIENT

Tommy Doran

L.D. McGill, DVM, Ph.D., DACVP
8288 Top of the World Drive
Cottonwood Heights, UT 84121
ldmcgill.vetpath@gmail.com
cell: 801-865-1220

SPECIES

Feline

BREED

DSH

SEX

Male Neutered

AGE

12y

WEIGHT

9.7#

HOSPITAL NAME

Rotterdam Veterinary
Hospital

REFERRING VET

Dr. Amy Scarpinato

INVOICE NUMBER

40541