



DATE **PRESENTING CLINICAL SIGNS**
6/13/22 V/D splenomegaly, 24 hour post vax.
ULTRASONOGRAPHIC FINDINGS

- Focal splenic nodule to monitor – hyperplasia likely, emerging round cell neoplasia or hemangiosarcoma possible.

INTERPRETED BY

L.D. McGill, DVM,
Ph.D, DACVP

CYTOLOGY SUBMISSION
FNA of Spleen

PATIENT **OBSERVATIONS**

Rocky Lynn

Spleen: Submitted are 3 excellent videos of moderate collections of cells from the nodule in the spleen in Rocky. The majority of the collection consists of red blood cells. There are small aggregates of cells that appear to be rounded cells to elongated cells. These are associated with platelets. In the surrounding red blood cells there is a mixture of round cells and neutrophils. Some of the cells are lymphocytes and some are nucleated red blood cells. Malignant criteria cannot be confirmed.

SPECIES

Canine

INTERPRETATION OF THE FINDINGS & FURTHER RECOMMENDATIONS

Spleen - Suggestive of fibrohistiocytic nodule with mild inflammation.

BREED

Terrier Mix

COMMENTS

The cellularity in this collection is mixed with small aggregates of cells that suggest the possibility of a fibrohistiocytic nodule. Some of the cells cause concern about the possibility of a low-grade hemangioma but with the mixture, I was unable to make that diagnosis. There is mild inflammation and there is a mixed cellular component. Continued monitoring of the nodule may be important since the cellularity is not specific. At this time, I am unable to identify changes that confirm malignancy.

AGE

7yr

WEIGHT

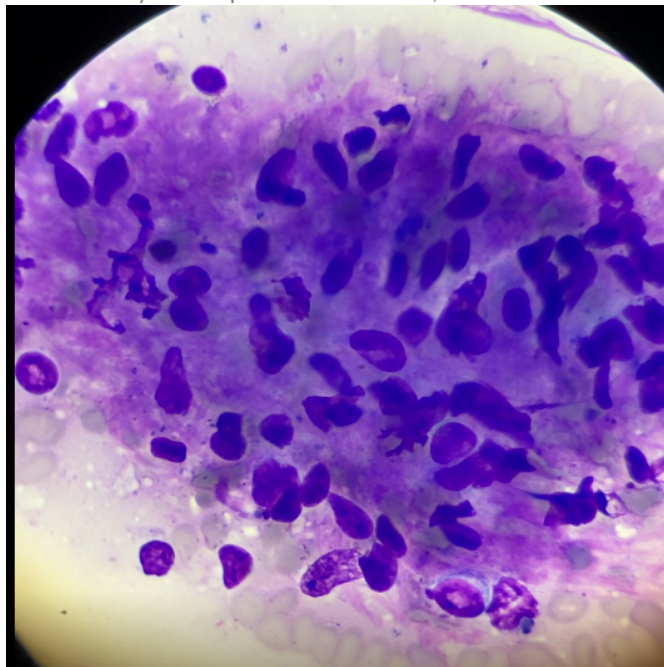
53.5#

HOSPITAL NAME

Rockaway Animal
Hospital

REFERRING VET

Dr Maniar



INVOICE NUMBER

40539

Image shows cells suggestive of a fibrohistiocytic nodule collected from Rocky. There are lymphoid cells in this aggregate.



DATE 6/13/22 The information and recommendations provided are based on the images presented by the referring veterinarian. No evaluation can be communicated regarding pathology that was not visible in the image/video clips provided.

INTERPRETED BY L.D. McGill, DVM, Ph.D., DACVP Thank you for this referral. If the clinical or image interpretation does not parallel your findings or if I can be of any further assistance, please contact me.

L.D. McGill, DVM,
Ph.D., DACVP

L.D. McGill, DVM, Ph.D., DACVP
8288 Top of the World Drive
Cottonwood Heights, UT 84121
ldmcgill.vetpath@gmail.com
cell: 801-865-1220

PATIENT
Rocky Lynn

SPECIES

Canine

BREED

Terrier Mix

SEX

Male Neutered

AGE

7yr

WEIGHT

53.5#

HOSPITAL NAME

Rockaway Animal
Hospital

REFERRING VET

Dr Maniar

INVOICE NUMBER

40539