

**DATE** **CYTOLOGY SUBMISSION**

6-12-22

U/S-Guided FNA: Left Kidney and Mesenteric Lymph Node

**INTERPRETED BY**

L.D. McGill, DVM,  
Ph.D, DACVP

**OBSERVATIONS**

Left kidney: Submitted are 4 excellent videos of excellent collections of cells from the left kidney in Maggie. The cellularity is almost entirely round cells. Many of the nuclei are naked nuclei but there are scattered cells that support lymphoid cells with minimal cytoplasm. The lymphoid cells are irregular in size and shape with many intermediate lymphoid cells. Degenerate debris with spindloid cells and macrophages can also be identified. Scattered lymphoid cells are quite large.

**PATIENT**

Maggie Cinquino

Mesenteric lymph node: Submitted are 4 excellent videos of moderate to excellent collections of cells from the mesenteric lymph node in Maggie. The majority the cells are small to intermediate. There are scattered large cells. Atypical cells are not prominent. Some of the cells are smudged and irregular. There are scattered neutrophils and rare macrophages. Atypical lymphoid cells are not identified.

**SPECIES**

Feline

**ULTRASONOGRAPHIC DIAGNOSIS**

Both kidneys revealed thickened irregular cortices with infarcts and subcapsular halo, primarily in the left kidney. This is strongly suggestive for infiltrative disease. Hypoechoic nodular changes were noted also in the renal cortex.

**BREED**

DMH

A mesenteric lymph node mass was noted, measuring 3.0 cm as a grouping of cluster of distorted hypoechoic lymph nodes with peripheral inflammation.

**SEX**

FS

**INTERPRETATION OF THE FINDINGS & FURTHER RECOMMENDATIONS**

Left kidney - Consistent with intermediate to high grade lymphoma of the kidney.  
Mesenteric lymph node - Consistent with reactive lymphoid tissue with mild inflammation.

**AGE**

16 yrs

**COMMENTS**

The cellular collection from the kidney is most consistent with a lymphoma. It appears to be high-grade to intermediate. This cellularity is quite prominent throughout all of these excellent smears with no suggestion of other sources for these cellular infiltrations. There is no suggestion of inflammation except for possible secondary change.

**WEIGHT**

5.4 lbs

Neoplastic cellularity is not confirmed in the lymph node but it is possible that it could be a part of the process. The lymph node tissue could be representing an early lymphoma or it may only be representative of a reactive lymphoid tissue. Immunophenotyping of these cells is encouraged to confirm the underlying process. This identification of the cell type may not be beneficial for prognosis but it may assist in confirming the diagnosis. An unfavorable prognosis is warranted, in my opinion, due to the marked lymphocytic cellular infiltration into the left kidney in Maggie.

**HOSPITAL NAME**

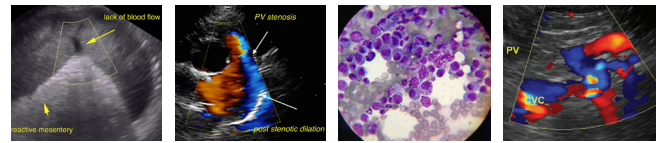
Animal Clinic of Flanders

**REFERRING VET**

Dr. Hallihan

**INVOICE NUMBER**

9094



**DATE**

6-12-22

**INTERPRETED BY**

L.D. McGill, DVM,  
Ph.D, DACVP

**PATIENT**

Maggie Cinquino

**SPECIES**

Feline

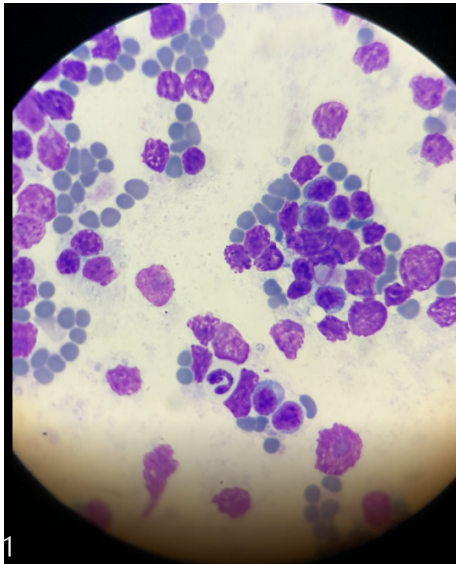


Image shows a representative group of cells collected from the left kidney. Most of these cells are lymphoid cells with some of the naked nuclei likely from this cell type.

**BREED**

DMH

**SEX**

FS

**AGE**

16 yrs

**WEIGHT**

5.4 lbs

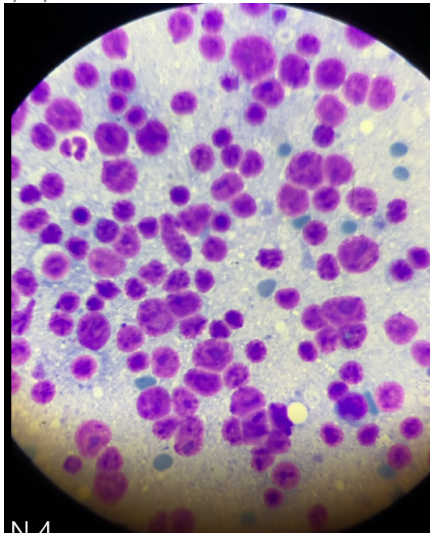


Image shows a representative collection of cells from the mesenteric lymph node in Maggie. There is a mixture of large and small to intermediate nuclei and possible early lymphoma.

**HOSPITAL NAME**

Animal Clinic of Flanders

**REFERRING VET**

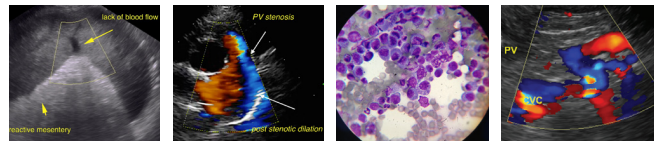
Dr. Hallihan

The information and recommendations provided are based on the images presented by the referring veterinarian. No evaluation can be communicated regarding pathology that was not visible in the image/video clips provided.

Thank you for this referral. If the clinical or image interpretation does not parallel your findings or if I can be of any further assistance please contact me.

**INVOICE NUMBER**

9094



**DATE** L.D. McGill, DVM, Ph.D., DACVP  
8288 Top of the World Drive  
6-12-22 Cottonwood Heights, UT 84121  
ldmcgill.vetpath@gmail.com  
cell: 801-865-1220

**INTERPRETED BY**

L.D. McGill, DVM,  
Ph.D, DACVP

**PATIENT**

Maggie Cinquino

**SPECIES**

Feline

**BREED**

DMH

**SEX**

FS

**AGE**

16 yrs

**WEIGHT**

5.4 lbs

**HOSPITAL NAME**

Animal Clinic of Flanders

**REFERRING VET**

Dr. Hallihan

**INVOICE NUMBER**

9094