

DATE PRESENTING CLINICAL SIGNS

6/12/22

ADR and weight loss

INTERPRETED BY CYTOLOGY SUBMISSION

U/S Guided FNA: Mesenteric LN

L.D. McGill, DVM,
Ph.D, DACVP

OBSERVATIONS

Mesenteric lymph node: Submitted are 8 excellent videos of moderate collections to excellent collections of cells from the mesenteric lymph node in BB. The cellularity is mixed with some of the fields demonstrating inflammatory cells including neutrophils and macrophages. There are some extremely large cells with large irregular nuclei. These cells are interspersed with lymphoid cells that are variable sized with many of them being quite large. These large lymphoid cells have nuclei that are 4 to 6 times the size of red blood cells with prominent nucleoli. Degenerate debris and inflammation are part of the process. These irregular lymphoid cells suggest the likelihood of neoplasia.

PATIENT

BB Blatt

SPECIES

Feline

ULTRASONOGRAPHIC DIAGNOSIS

U/S findings: Mesenteric LN enlargement and suspect enlarged spleen.

BREED

DSH

INTERPRETATION OF THE FINDINGS & FURTHER RECOMMENDATIONS

Mesenteric lymph node - Suggestive of high-grade lymphoma and possible Hodgkins-like lymphoma.

SEX

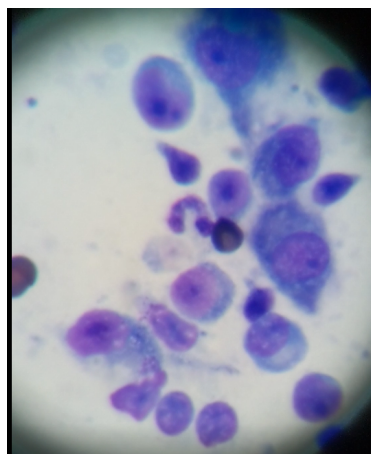
Male Neutered

COMMENTS

The cellularity has many characteristics that are supportive of a high-grade lymphoma. The extremely large cells suggest the possibility of a Hodgkins -like lymphoma in the mesenteric lymph node of BB. There is extensive inflammation which could be draining from the intestine or other sources. The cellularity can be confirmed with immunophenotyping of the cells. These smears can be sent off for PARR testing. An unfavorable prognosis is warranted in my opinion. With the marked inflammation, I suspect that other organs in the abdominal cavity are involved which may include the intestine or pancreas.

WEIGHT

8 lbs



HOSPITAL NAME

Franklin Animal Clinic

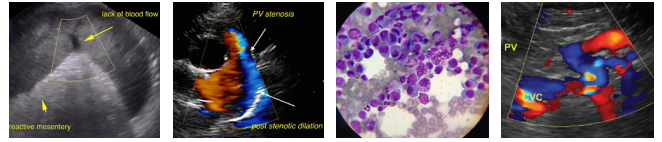
REFERRING VET

Dr. Doverspike

INVOICE NUMBER

9092

Image shows a group of large irregular lymphoid cells with large nuclei and nucleoli. Comparison with the neutrophil in the center suggests very large lymphoid cells.



DATE

6/12/22

INTERPRETED BY

L.D. McGill, DVM,
Ph.D., DACVP

The information and recommendations provided are based on the images presented by the referring veterinarian. No evaluation can be communicated regarding pathology that was not visible in the image/video clips provided.

Thank you for this referral. If the clinical or image interpretation does not parallel your findings or if I can be of any further assistance please contact me.

PATIENT

BB Blatt

L.D. McGill, DVM, Ph.D., DACVP
8288 Top of the World Drive
Cottonwood Heights, UT 84121
ldmcgill.vetpath@gmail.com
cell: 801-865-1220

SPECIES

Feline

BREED

DSH

SEX

Male Neutered

AGE

13 yrs

WEIGHT

8 lbs

HOSPITAL NAME

Franklin Animal Clinic

REFERRING VET

Dr. Doverspike

INVOICE NUMBER

9092