



DATE PRESENTING CLINICAL SIGNS

6/1/22 Princess Buttercup presented to BAESC for AUS on referral basis for the following concerns:
5/13/2022 presented to EBAH for Chief complaint (problem):
--not acting herself
--lethargic

INTERPRETED BY -- not grooming herself
-- Nictitating membrane present OU

L.D. McGill, DVM, Ph.D, DACVP Onset/duration: hard to tell, O's son was taking care of her while O was in hospital Approx. started 2 weeks ago. Client can recall that 3 to 6 months ago, she was thriving.

PATIENT CYTOLOGY SUBMISSION

Princess Buttercup
Meadows FNA of Spleen

OBSERVATIONS

SPECIES Spleen: Submitted are 4 excellent videos of moderate to excellent collections of cells from the spleen in Princess Buttercup. The cellularity is mixed throughout all of these videos. There are neutrophils, nucleated red blood cells, lymphocytes, plasma cells and scattered macrophages. Atypical malignant cells are not identified. There are some large reactive lymphoid cells but they are not atypical. Even scattered eosinophils are identified.

Feline

BREED

DLH **INTERPRETATION OF THE FINDINGS & FURTHER RECOMMENDATIONS**
Spleen - Mixed cell collection with evidence of mild splenitis and hematopoiesis.

SEX COMMENTS

F S The changes in the spleen are not specific for any process. There is no suggestion of malignancy or sepsis. There may be problems of malignancy in other locations in Princess Buttercup, but they are not present in the spleen. Some of the clinical signs cause concern about the potential of cerebral abnormalities. I am unable to identify any primary process in the spleen. If problems continue, evaluation of other organs is encouraged. A guarded prognosis is warranted since we do not know the underlying cause of problems in Princess Buttercup.

AGE

8 years 9 months

WEIGHT

5.1 kg

HOSPITAL NAME

Smiling Dog Veterinary
Services

REFERRING VET

Dr. Laurie Langford
DVM

INVOICE NUMBER

40532



DATE

6/1/22

INTERPRETED BY

L.D. McGill, DVM,
Ph.D, DACVP

PATIENT

Princess Buttercup
Meadows

SPECIES

Feline

BREED

DLH

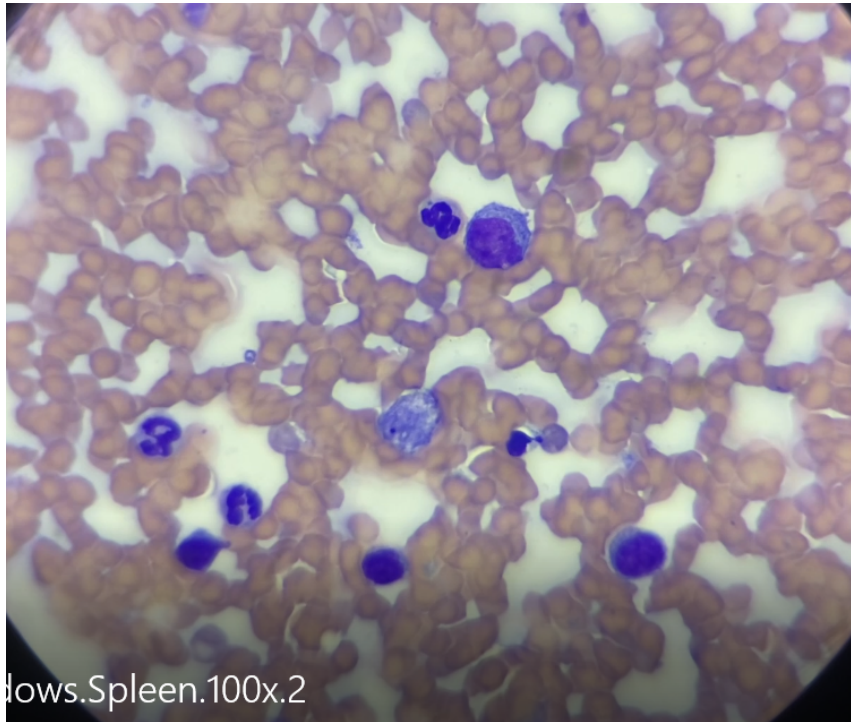


Image shows a few cells that are identified in the collection from the spleen in Princess Buttercup. There are neutrophils with lymphocytes that are reactive.

SEX

F S

The information and recommendations provided are based on the images presented by the referring veterinarian. No evaluation can be communicated regarding pathology that was not visible in the image/video clips provided.

AGE

8 years 9 months

Thank you for this referral. If the clinical or image interpretation does not parallel your findings or if I can be of any further assistance, please contact me.

WEIGHT

5.1 kg

L.D. McGill, DVM, Ph.D., DACVP
8288 Top of the World Drive
Cottonwood Heights, UT 84121
ldmcgill.vetpath@gmail.com
cell: 801-865-1220

HOSPITAL NAME

Smiling Dog Veterinary
Services

REFERRING VET

Dr. Laurie Langford
DVM

INVOICE NUMBER

40532