



DATE **PRESENTING CLINICAL SIGNS**
6/1/22 Elevated ALT and bile acids. No current meds.
ALT >600, post-prandial bile acid >100. Lepto PCR pending

INTERPRETED BY **CYTOLOGY SUBMISSION**
L.D. McGill, DVM, Ph.D, DACVP FNA of Liver

PATIENT **OBSERVATIONS**
Molly Horan Liver: Submitted are 4 excellent videos of minimal cellular collections from the liver in Molly. The hepatocytes that can be identified are demonstrating slight vacuolization and granularity but in general are within normal limits. Bile retention was not identified. There are scattered inflammatory cells in the surrounding red blood cells but no suggestion of neoplasia or other marked abnormality.

SPECIES **INTERPRETATION OF THE FINDINGS & FURTHER RECOMMENDATIONS**
Canine Liver - Mild hepatocellular vacuolization and granularity with very mild inflammation.

BREED **COMMENTS**
Cockapoo The cellularity in this collection demonstrated a few aggregates of hepatocytes. Those hepatocytes appear to be within normal limits to slightly vacuolated and granular. There was no suggestion of bile retention within the hepatocytes. I was unable to identify any primary change that would include neoplasia or sepsis. There may be copper present, but I am unable to confirm. Hepatic biopsy will likely be required to confirm the underlying process. A guarded prognosis is warranted in light of the clinical problems.

SEX
F-intact

AGE
1yr

WEIGHT
13#

HOSPITAL NAME
Tranquility Veterinary Clinic

REFERRING VET
Dr. Christensen

INVOICE NUMBER
40533

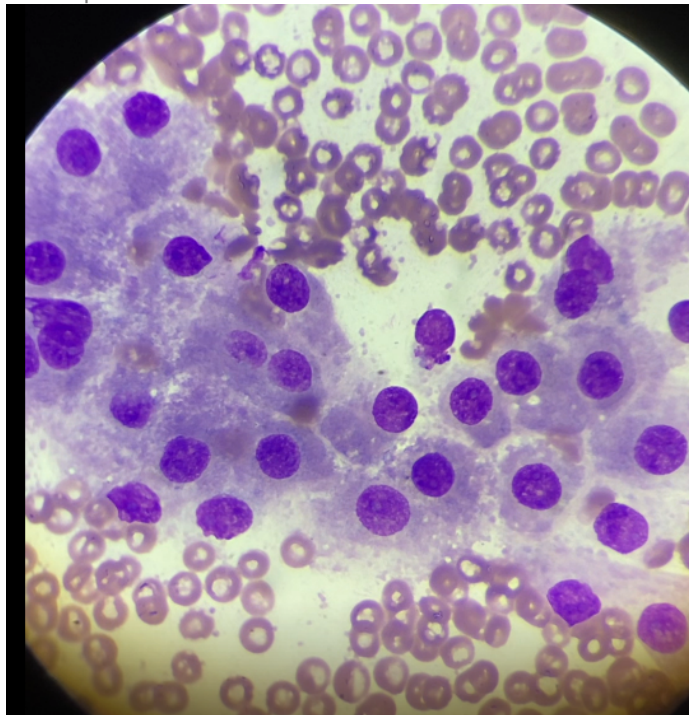


Image shows a representative collection of hepatocytes with slight vacuolization and granularity collected from the liver in Molly. Changes are minimal.



DATE

6/1/22

The information and recommendations provided are based on the images presented by the referring veterinarian. No evaluation can be communicated regarding pathology that was not visible in the image/video clips provided.

INTERPRETED BY

L.D. McGill, DVM,
Ph.D., DACVP

Thank you for this referral. If the clinical or image interpretation does not parallel your findings or if I can be of any further assistance, please contact me.

PATIENT

Molly Horan

L.D. McGill, DVM, Ph.D., DACVP
8288 Top of the World Drive
Cottonwood Heights, UT 84121
ldmcgill.vetpath@gmail.com
cell: 801-865-1220

SPECIES

Canine

BREED

Cockapoo

SEX

F-intact

AGE

1yr

WEIGHT

13#

HOSPITAL NAME

Tranquility Veterinary
Clinic

REFERRING VET

Dr. Christensen

INVOICE NUMBER

40533