



DATE PRESENTING CLINICAL SIGNS

5/9/23

The right thyroid lobe revealed a separate cyst that measured 1.2 cm with a proliferative tissue enlargement that measured 2.74 x 1.38 cm . left thyroid lobe revealed a large cyst that measured 3.0 cm with round, irregular tissue surrounding the cyst. FNA of right thyroid lobe; suspected thyroid tumor .

INTERPRETED BY

L.D. McGill, DVM,
Ph.D, DACVP

CYTOLOGY SUBMISSION

FNA of right thyroid lobe

PATIENT

Riley Jackson

OBSERVATIONS

Thyroid gland: Submitted are 6 excellent videos of moderate cellular collection from the thyroid glandular region in Riley. The cellularity consists of large numbers of red blood cells interspersed with a mixture of nucleated cells. There are scattered inflammatory cells. The majority of the cells are slightly elongated epithelial cells with round to slightly oblong nuclei. The cells demonstrate anisokaryosis and anisocytosis. Occasionally the cells are individualized. There are groups of cells that are associated with a packet of eosinophilic material. This is a characteristic proliferative process with hemorrhage from the thyroid gland region.

SPECIES

Canine

BREED

Lhasa Apsa

INTERPRETATION OF THE FINDINGS & FURTHER RECOMMENDATIONS

Thyroid gland - Consistent with thyroid carcinoma with inflammation and hemorrhage

SEX

Male Neutered

COMMENTS

The cellularity is strongly suggestive of a thyroid gland carcinoma. There is hemorrhage which is common with this type of a neoplastic process. The cystic structure easily could be a secondary cyst within the neoplastic process or could be secondary to necrosis. Excision of the mass and follow-up biopsy is encouraged to confirm the diagnosis. This is also beneficial in therapy. There are some cases where these tumors will metastasize to the pulmonary tissue and further evaluation for that potential is encouraged. A guarded prognosis is warranted due to the potential of metastasis.

WEIGHT

16.6#

HOSPITAL NAME

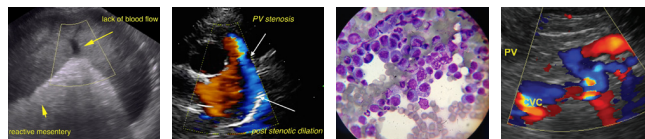
Animal Care Centers of
Flanders

REFERRING VET

Dr. Hallihan

INVOICE NUMBER

40725



DATE

5/9/23

INTERPRETED BY

L.D. McGill, DVM,
Ph.D, DACVP

PATIENT

Riley Jackson

SPECIES

Canine

BREED

Lhasa Apsa

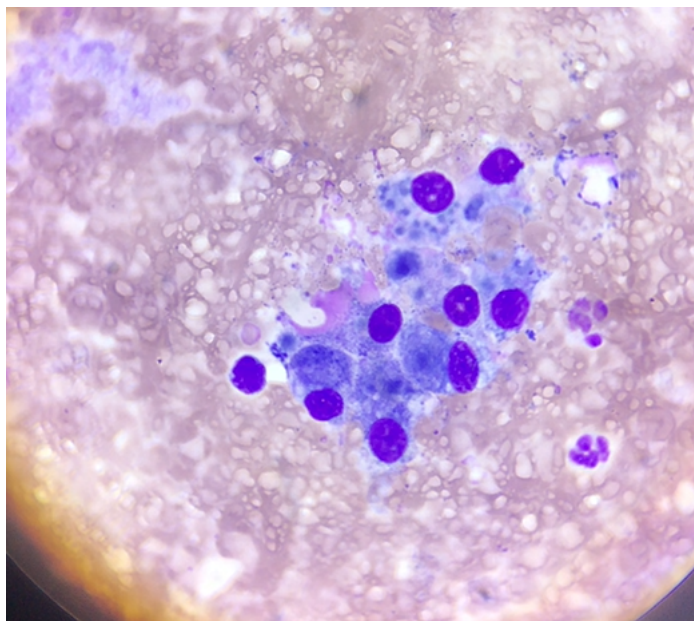


Image demonstrates a group of neoplastic epithelial cells with eosinophilic material that is likely thyroglobulin surrounded by red blood cells and inflammatory cells. Note the anisocytosis and anisokaryosis of the likely proliferative cells.

SEX

Male Neutered

The information and recommendations provided are based on the images presented by the referring veterinarian. No evaluation can be communicated regarding pathology that was not visible in the image/video clips provided.

AGE

15 year

Thank you for this referral. If the clinical or image interpretation does not parallel your findings or if I can be of any further assistance, please contact me.

WEIGHT

16.6#

L.D. McGill, DVM, Ph.D., DACVP
8288 Top of the World Drive
Cottonwood Heights, UT 84121
ldmcgill.vetpath@gmail.com
cell: 801-865-1220

HOSPITAL NAME

Animal Care Centers of
Flanders

REFERRING VET

Dr. Hallihan

INVOICE NUMBER

40725