



DATE PRESENTING CLINICAL SIGNS

5/9/23

ADR past several days; Was vomiting but not now
SDMA 33 µg/dL 0 - 14 HIGH
CREA 2.8 mg/dL 0.5 - 1.8 HIGH
BUN 54 mg/dL 7 - 27 HIGH
PHOS 4.4 mg/dL 2.5 - 6.8
CA > 16.0 mg/dL 7.9 - 12.0 HIGH
CRP 2.6 mg/dL 0.0 - 1.0 HIGH
Leukopenia and Thrombocytopenia

INTERPRETED BY

L.D. McGill, DVM,
Ph.D, DACVP

PATIENT

Hudson O'Donnell

CYTOLOGY SUBMISSION

FNA of Spleen

SPECIES

Canine

OBSERVATIONS

Spleen: Submitted are 9 excellent videos of excellent collections of cells from the spleen in Hudson. The cellularity in general consists of large numbers of round cells. There are scattered neutrophils and macrophages with a few small mature lymphocytes. The majority of the cells are large round cells with nuclei that are 4 to 8 times the size of red blood cells. Occasionally these nuclei are even larger. Occasional clefted nuclei are collected. The large round cells are approximately 60% of the cellularity in this collection. There are scattered nucleated RBCs in the collection. The large round cells have prominent irregular nucleoli. Scattered mitotic figures were identified.

BREED

Labrador Retriever

SEX

Male Neutered

INTERPRETATION OF THE FINDINGS & FURTHER RECOMMENDATIONS

Spleen - Characteristic of high-grade lymphoma

AGE

5y

COMMENTS

The cellularity in this excellent collection includes large numbers of large round cells that are characteristic of lymphoblasts. Many of these cells are large and some have granular cytoplasm. They could be neoplastic cells of large granular lymphocytes or other types of neoplastic round cells. There is some secondary degeneration and inflammation. If therapy is being considered, further evaluation of the cell type is encouraged by immunophenotyping these cells. This can be accomplished on these slides or with the re-collection of cells. Flow cytometry can be utilized and will require a new collection of cells. An unfavorable prognosis is warranted in my opinion with these cells in this collection from Hudson. There is a possibility that he may respond to therapy early but long-term is expected to be unfavorable.

WEIGHT

80.bs

HOSPITAL NAME

Franklin Animal Clinic
Inc.

REFERRING VET

Dr. Sam Doverspike

INVOICE NUMBER

40723



DATE

5/9/23

INTERPRETED BY

L.D. McGill, DVM,
Ph.D, DACVP

PATIENT

Hudson O'Donnell

SPECIES

Canine

BREED

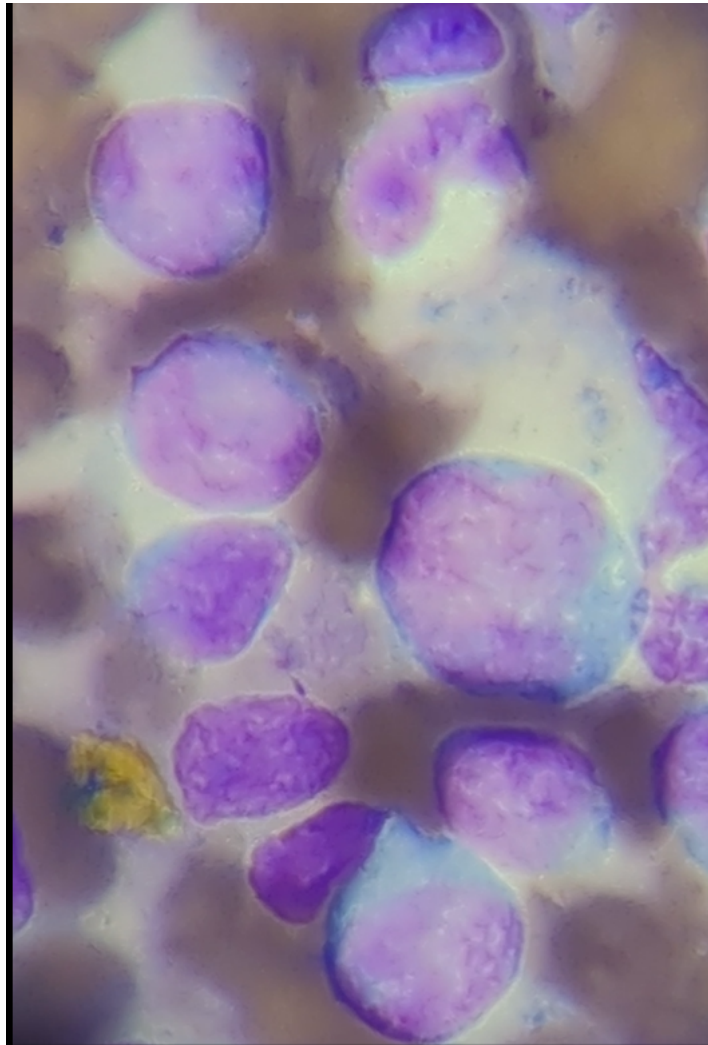
Labrador Retriever

SEX

Male Neutered

AGE

5y



WEIGHT

80.bs

Image shows a group of cells collected from the spleen in Hudson. The extremely large cells are neoplastic round cells with prominent irregular nucleoli. There are small lymphocytes in the collection with a small collection of hemosiderin to the left.

The information and recommendations provided are based on the images presented by the referring veterinarian. No evaluation can be communicated regarding pathology that was not visible in the image/video clips provided.

HOSPITAL NAME

Franklin Animal Clinic
Inc.

Thank you for this referral. If the clinical or image interpretation does not parallel your findings or if I can be of any further assistance, please contact me.

REFERRING VET

Dr. Sam Doverspike

L.D. McGill, DVM, Ph.D., DACVP
8288 Top of the World Drive
Cottonwood Heights, UT 84121
ldmcgill.vetpath@gmail.com
cell: 801-865-1220

INVOICE NUMBER

40723



DATE

5/9/23

INTERPRETED BY

L.D. McGill, DVM,
Ph.D, DACVP

PATIENT

Hudson O'Donnell

SPECIES

Canine

BREED

Labrador Retriever

SEX

Male Neutered

AGE

5y

WEIGHT

80.bs

HOSPITAL NAME

Franklin Animal Clinic
Inc.

REFERRING VET

Dr. Sam Doverspike

INVOICE NUMBER

40723