



DATE PRESENTING CLINICAL SIGNS

5/8/23 Presented for ER for frequent trips to the litter box. Blood work relatively normal. Clinician found cystic mass mid-abdomen while doing a cystocentesis. Cat is doing better now, acting normally. CBC/Chem: WNL except BG 182. RADS (today): WNL

INTERPRETED BY

AUS: apx 5cm x 4cm cyst, located near base of mesentery. USG drainage yielded apx. 20mL opaque white fluid, TP 7.5.

L.D. McGill, DVM,
Ph.D, DACVP

Cytospin done for cytology.

CYTOLOGY SUBMISSION

Pancreatic cyst

PATIENT

Topaz Dean

OBSERVATIONS

Pancreas: Submitted are 6 very good videos of minimal cellular collections from the cystic structure near the pancreas in Topaz. The cellularity is minimal. There is a prominent collection of lipid and saponified lipid debris. There are scattered inflammatory cells which are few in numbers. One video demonstrates good numbers of reactive macrophages. They have foamy cytoplasm. There is no suggestion of malignancy. Nor did I identify adequate numbers of lymphoid cells.

SPECIES

Feline

INTERPRETATION OF THE FINDINGS & FURTHER RECOMMENDATIONS

Pancreas - Pancreatic cyst with digested fat tissue and macrophages.

BREED

Ragdoll

COMMENTS

The cellularity is minimal but where there are cells, they are macrophages or possibly other chronic inflammatory cells. There is no suggestion of malignancy nor does the fluid support chylous fluid. It is most characteristic of fat tissue that is degenerate with macrophages. This is likely the result of a localized pancreatic enzyme release resulting in saponified fat tissue in the region. I strongly suspect that this is another case of unusual localized pancreatitis. Once the fluid cyst was drained, the cat will feel better. Continued monitoring for additional potential of pancreatitis is encouraged.

SEX

Female Spayed

AGE

15y11mo

WEIGHT

10.7 lbs

HOSPITAL NAME

Scanvet

REFERRING VET

Dr. Holden

INVOICE NUMBER

945



DATE

5/8/23

INTERPRETED BY

L.D. McGill, DVM,
Ph.D, DACVP

PATIENT

Topaz Dean

SPECIES

Feline

BREED

Ragdoll

SEX

Female Spayed

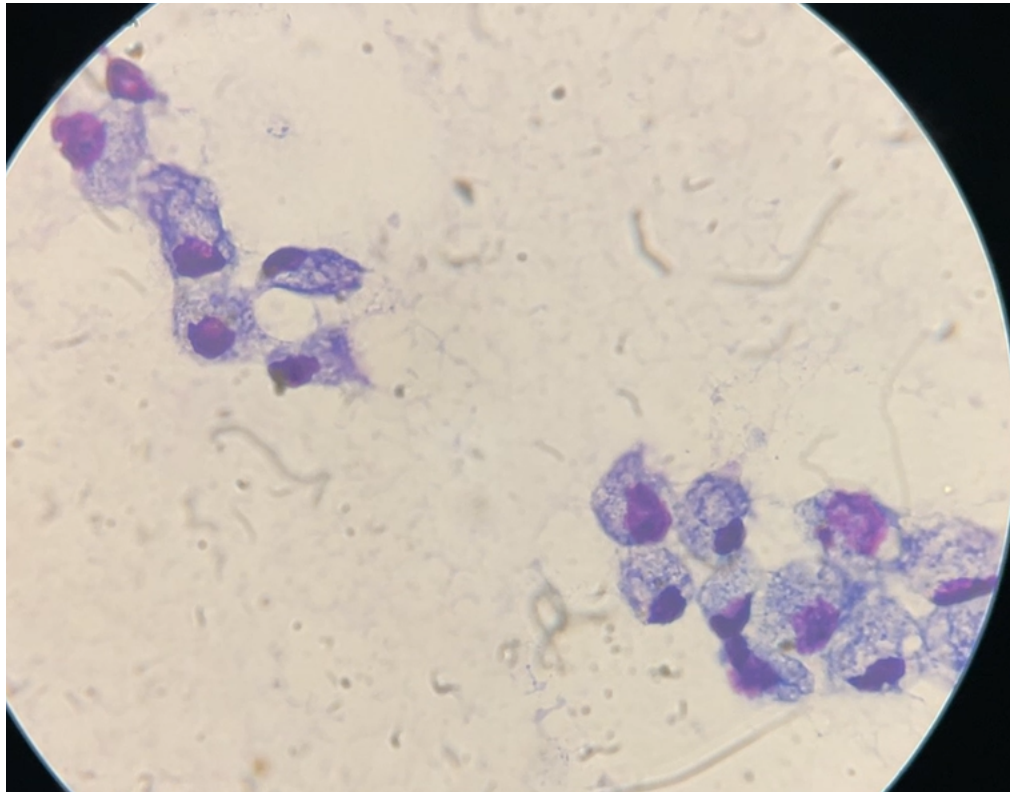


Image shows some of the better cells collected from Topaz. These are macrophages with a foamy cytoplasm. They may be reactive mesothelial cells.

AGE

15y11mo

The information and recommendations provided are based on the images presented by the referring veterinarian. No evaluation can be communicated regarding pathology that was not visible in the image/video clips provided.

WEIGHT

10.7 lbs

Thank you for this referral. If the clinical or image interpretation does not parallel your findings or if I can be of any further assistance please contact me.

HOSPITAL NAME

Scanvet

L.D. McGill, DVM, Ph.D., DACVP
8288 Top of the World Drive
Cottonwood Heights, UT 84121
ldmcgill.vetpath@gmail.com
cell: 801-865-1220

REFERRING VET

Dr. Holden

INVOICE NUMBER

945