

DATE **PRESENTING CLINICAL SIGNS**
5/8/22 Liver failure, gastroenteritis

INTERPRETED BY **CYTOLOGY SUBMISSION**
L.D. McGill, DVM, Ph.D, DACVP U/S Guided FNA: Liver

PATIENT **OBSERVATIONS**
Lucy Daniels Liver: Submitted are 4 excellent videos of moderate to excellent collections of hepatocytes from the liver in Lucy. The hepatocytes are associated with large numbers of RBCs interspersed with inflammatory cells that are neutrophils and lymphocytes. The hepatocytes demonstrate slightly granular cytoplasm with prominent anisokaryosis and anisocytosis. The cellularity is aggregated in irregular patterns and not demonstrating chainlike patterns of growth. This cellularity is slightly irregular. No other atypical cellularity is identified in the smears except for possible secondary inflammation.

SPECIES
Canine

BREED **ULTRASONOGRAPHIC DIAGNOSIS**
Shih Tzu The liver revealed multifocal cystic and mixed hypoechoic complex masses, occupying the majority of the liver and deviating the diaphragm. Ill-defined margins noted. The masses expanded to approximately 10 cm, non-resectable. The masses occupied the left cranial and right cranial liver.

SEX
Spayed Female

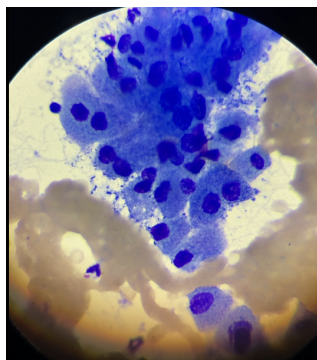
INTERPRETATION OF THE FINDINGS & FURTHER RECOMMENDATIONS
Hepatocellular proliferation suggestive of hepatocellular carcinoma.

AGE
12yrs
WEIGHT
23 lbs

COMMENTS
The changes in the liver suggest the likelihood of a hepatocellular proliferative process such as a hepatocellular carcinoma. There is a possibility that this could be a hepatocellular adenoma, but this will require a follow-up biopsy of hepatic tissue to confirm. At this time, I am concerned about the potential in Lucy and thus suggest a guarded to unfavorable prognosis. An exploratory of the region may be beneficial in confirming the specific underlying process.

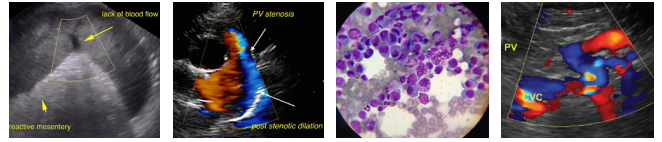
HOSPITAL NAME
Rockaway Animal Hospital

REFERRING VET
Dr. Maniar



INVOICE NUMBER Image shows some of the hepatocytes collected from Lucy. Note the anisocytosis and anisokaryosis in the cells and the disorganized growth.

9090



DATE

5/8/22

INTERPRETED BY

L.D. McGill, DVM,
Ph.D, DACVP

The information and recommendations provided are based on the images presented by the referring veterinarian. No evaluation can be communicated regarding pathology that was not visible in the image/video clips provided.

Thank you for this referral. If the clinical or image interpretation does not parallel your findings or if I can be of any further assistance please contact me.

PATIENT

Lucy Daniels

L.D. McGill, DVM, Ph.D., DACVP
8288 Top of the World Drive
Cottonwood Heights, UT 84121
ldmcgill.vetpath@gmail.com
cell: 801-865-1220

SPECIES

Canine

BREED

Shih Tzu

SEX

Spayed Female

AGE

12yrs

WEIGHT

23 lbs

HOSPITAL NAME

Rockaway Animal
Hospital

REFERRING VET

Dr. Maniar

INVOICE NUMBER

9090