



DATE PRESENTING CLINICAL SIGNS

5/5/23

Large, hyperechoic liver, coarse. Increased liver enzymes.

CYTOLOGY SUBMISSION

Liver

INTERPRETED BY

L.D. McGill, DVM,
Ph.D, DACVP

OBSERVATIONS

Liver: Submitted are 5 excellent videos of excellent collections of hepatocytes from the liver in Nayla. The hepatocytes demonstrate slight vacuolization and slight granularity. There are some binucleate cells and some suggestions of nodular hyperplasia. Occasional spindloid cells suggest the possibility of fibrosis. The associated cells in the surrounding fluid are mixed including neutrophils and lymphocytes. Malignant characteristics or sepsis are not identified.

PATIENT

Nayla Powell

INTERPRETATION OF THE FINDINGS & FURTHER RECOMMENDATIONS

Liver - Suggestive of nodular hyperplasia with mild hepatocellular vacuolization and granularity and mild fibrosis.

SPECIES

Canine

COMMENTS

The changes in these excellent collections of hepatocytes suggest the possibility of metabolic liver disease process and nodular hyperplasia. There is no suggestion of malignancy or sepsis. The cellular changes could be secondary to problems in other organs including the pancreas or the intestine.

BREED

Mix

Endotoxins from either organ could cause problems. There is a possibility that the liver is maturing and there could be some cell membrane abnormalities in Nayla. This could allow for leakage of liver enzymes through weakened cell membranes. My suspicion is that the liver is responding secondarily and there may be some fibrosis and nodular hyperplasia but no other primary liver cellular changes are noted. Continued evaluation of Nayla for problems in other organs is encouraged.

SEX

Female Spayed

AGE

10y

WEIGHT

31.6

HOSPITAL NAME

Rotterdam Veterinary
Hospital

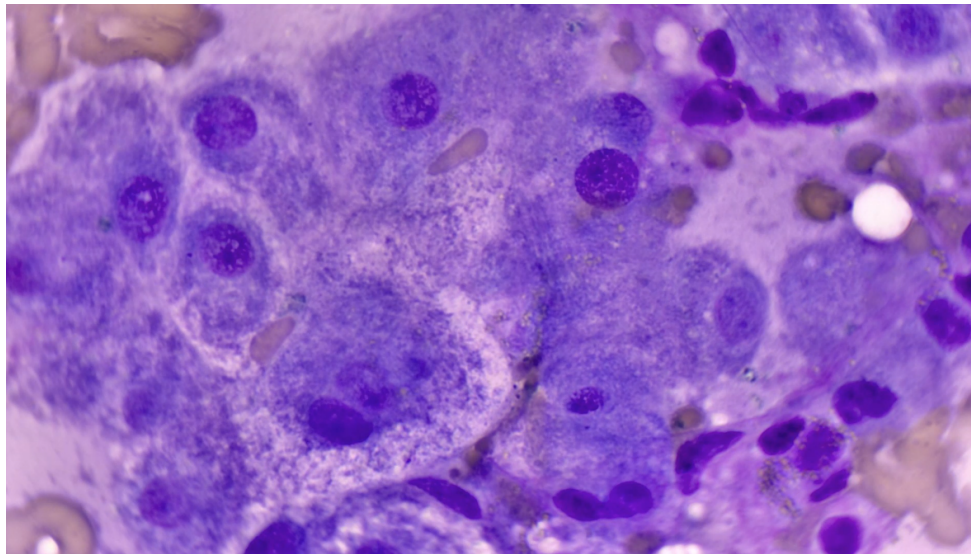


Image shows a group of hepatocytes collected from the liver in Nayla. There is some irregularity of the hepatocytes and a suggestion of fibrosis.

REFERRING VET

Dr. St. Sir

The information and recommendations provided are based on the images presented by the referring veterinarian. No evaluation can be communicated regarding pathology that was not visible in the image/video clips provided.

INVOICE NUMBER

944



DATE

5/5/23

Thank you for this referral. If the clinical or image interpretation does not parallel your findings or if I can be of any further assistance please contact me.

INTERPRETED BY

L.D. McGill, DVM,
Ph.D, DACVP

L.D. McGill, DVM, Ph.D., DACVP
8288 Top of the World Drive
Cottonwood Heights, UT 84121
ldmcgill.vetpath@gmail.com
cell: 801-865-1220

PATIENT

Nayla Powell

SPECIES

Canine

BREED

Mix

SEX

Female Spayed

AGE

10y

WEIGHT

31.6

HOSPITAL NAME

Rotterdam Veterinary
Hospital

REFERRING VET

Dr. St. Sir

INVOICE NUMBER

944