



DATE PRESENTING CLINICAL SIGNS

5/5/23

Patient presented for abdominal U/S 5/5/23. Spleen enlarged (1.2 cm) and coarse. Elevated ALT, AST, and ALP

INTERPRETED BY CYTOLOGY SUBMISSION

L.D. McGill, DVM,
Ph.D, DACVP

FNA of Spleen

PATIENT

Jeter Zoulas

OBSERVATIONS

Spleen: Submitted are 12 images of cells collected from the spleen in Jeter. There is a mixed population of cells. Many of the cells are smudged and difficult to identify. Some of the cells are large and appear to be macrophages. There is one long structure that appears to be a vessel. Interspersed throughout the macrophages are scattered lymphocytes and neutrophils. There is no suggestion of neoplasia in the cellular collection that I could evaluate. There is a suggestion of chronic inflammation.

SPECIES

Feline

INTERPRETATION OF THE FINDINGS & FURTHER RECOMMENDATIONS

Spleen - The cellularity is mixed with evidence of granulomatous inflammation and neutrophils.

BREED

DSH

COMMENTS

The cellularity is supporting a chronic inflammatory process or nonspecific reaction to the spleen. This could be secondary to many different conditions. This could be from inflammation in the abdominal cavity or is some type of systemic inflammatory process. The histiocytic cells could suggest malignancy, but I cannot confirm that process. If problems continue, then further evaluation of the spleen is suggested with splenectomy and biopsy. My concern is that there are changes or inflammatory processes in other organs such as the pancreas or the intestine causing these changes secondarily. A guarded prognosis is warranted in Jeter.

SEX

Male Neutered

AGE

6y

WEIGHT

14.8 lb

HOSPITAL NAME

Rotterdam Veterinary
Hospital

REFERRING VET

Dr. Anna St.Sir

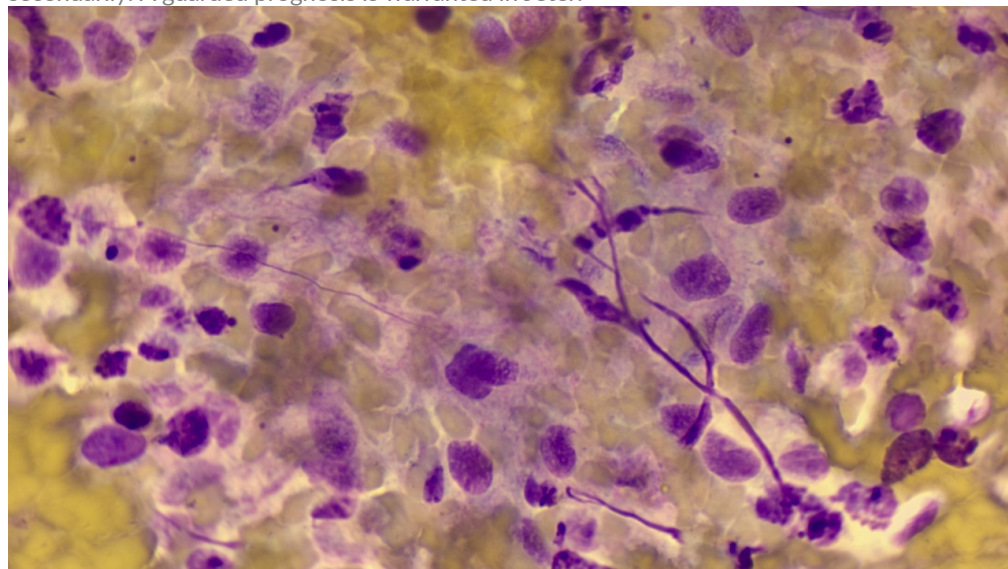


Image shows cells collected from the spleen in Jeter. Note the macrophages with scattered lymphocytes and neutrophils. There appear to be prominent platelets as well.

INVOICE NUMBER

40719



DATE 5/5/23 The information and recommendations provided are based on the images presented by the referring veterinarian. No evaluation can be communicated regarding pathology that was not visible in the image/video clips provided.

INTERPRETED BY L.D. McGill, DVM, Ph.D., DACVP Thank you for this referral. If the clinical or image interpretation does not parallel your findings or if I can be of any further assistance, please contact me.

L.D. McGill, DVM,
Ph.D., DACVP

L.D. McGill, DVM, Ph.D., DACVP
8288 Top of the World Drive
Cottonwood Heights, UT 84121
ldmcgill.vetpath@gmail.com
cell: 801-865-1220

PATIENT

Jeter Zoulas

SPECIES

Feline

BREED

DSH

SEX

Male Neutered

AGE

6y

WEIGHT

14.8 lb

HOSPITAL NAME

Rotterdam Veterinary
Hospital

REFERRING VET

Dr. Anna St.Sir

INVOICE NUMBER

40719