



**DATE PRESENTING CLINICAL SIGNS**

5/5/22

caudal to base of left pinna, 4cm firm alopecia mass, SQ and round well circumscribed, appeared 2 months ago and growing rapidly since. not painful

**INTERPRETED BY**

**CYTOLOGY SUBMISSION**

FNA of Dermal/Skin mass

L.D. McGill, DVM,  
Ph.D, DACVP

**OBSERVATIONS**

Skin mass: Submitted are 8 very good images of cells collected from the skin mass at the base of the left pinna on Blue. The cellularity demonstrates round nuclei with minimal cytoplasm. In many locations the cells are aligning in chainlike patterns. In others they are aggregated. The cellularity is irregular with minimal anisocytosis. Occasionally there is some eosinophilic background to these cells.

**PATIENT**

Blue Leclair

**INTERPRETATION OF THE FINDINGS & FURTHER RECOMMENDATIONS**

Skin mass - Packets of epithelial cells consistent with basal cell tumor.

**SPECIES**

Canine

**COMMENTS**

The cellularity in these collections suggests the likelihood of a basal cell tumor or trichoepithelioma. These nuclei and cells demonstrate a low-grade proliferative process. This also fits with a basal cell tumor. Excision of the mass is encouraged after evaluating this cytologic collection. Margins should not have to be very wide. A favorable prognosis is expected if the growth is completely excised.

**BREED**

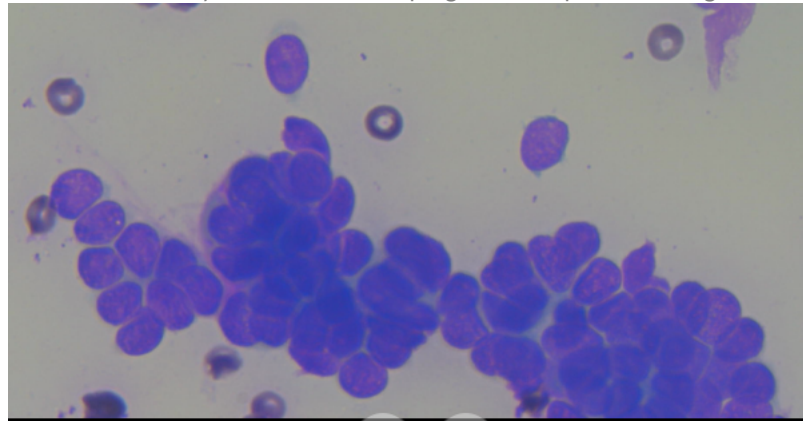
Beagle mix

**SEX**

Male Neutered

**AGE**

7y



**WEIGHT**

47#

Image shows packets of cells with some chain-like patterns of growth in the cells collected from Blue. Other aggregates are disorganized.

**HOSPITAL NAME**

Torch Lake Veterinary  
Clinic

The information and recommendations provided are based on the images presented by the referring veterinarian. No evaluation can be communicated regarding pathology that was not visible in the image/video clips provided.

Thank you for this referral. If the clinical or image interpretation does not parallel your findings or if I can be of any further assistance, please contact me.

**REFERRING VET**

Dr. Jennifer Rudnick

L.D. McGill, DVM, Ph.D., DACVP  
8288 Top of the World Drive  
Cottonwood Heights, UT 84121  
ldmcgill.vetpath@gmail.com  
cell: 801-865-1220

**INVOICE NUMBER**

40517



**DATE**

5/5/22

**INTERPRETED BY**

L.D. McGill, DVM,  
Ph.D, DACVP

**PATIENT**

Blue Leclair

**SPECIES**

Canine

**BREED**

Beagle mix

**SEX**

Male Neutered

**AGE**

7y

**WEIGHT**

47#

**HOSPITAL NAME**

Torch Lake Veterinary  
Clinic

**REFERRING VET**

Dr. Jennifer Rudnick

**INVOICE NUMBER**

40517